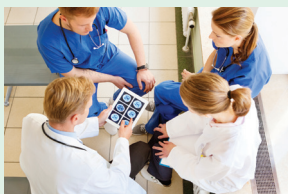

Glioblastoma: Overview of Disease and Treatment

Mary Elizabeth Davis, RN, MSN, CHPN, AOCNS®



© alvarez/iStockphoto.com

Background: Glioblastoma (GBM) is the most common and aggressive malignant brain tumor in adults. Current treatment options at diagnosis are multimodal and include surgical resection, radiation, and chemotherapy. Significant advances in the understanding of the molecular pathology of GBM and associated cell signaling pathways have opened opportunities for new therapies for recurrent and newly diagnosed disease. Innovative treatments, such as tumor-treating fields (TTFields) and immunotherapy, give hope for enhanced survival.

Objectives: This article reviews the background, risks, common complications, and treatment options for GBM.

Methods: A brief review of GBM, treatment options, and a look at new therapies that have been approved for new and recurrent disease are included in this article.

Findings: Despite aggressive resection and combined modality adjuvant treatment, most GBMs recur. Treatments, such as TTFields, drugs to target molecular receptors, and immunotherapy, are promising new options.

Mary Elizabeth Davis, RN, MSN, CHPN, AOCNS®, is a clinical nurse specialist at Memorial Sloan Kettering Cancer Center in New York, NY. The author takes full responsibility for the content of the article. This research was funded, in part, by a support grant (P30 CA008748) from the National Institutes of Health/National Cancer Institute. Editorial support was provided by Stephen Swyberius, BA, copy supervisor at PharmaHealthLabs, through support from Novocure, Inc. The content of this article has been reviewed by independent peer reviewers to ensure that it is balanced, objective, and free from commercial bias. No financial relationships relevant to the content of this article have been disclosed by the independent peer reviewers or editorial staff. Mention of specific products and opinions related to those products do not indicate or imply endorsement by the *Clinical Journal of Oncology Nursing* or the Oncology Nursing Society. Davis can be reached at davism@mskcc.org, with copy to editor at CJONEditor@ons.org. (Submitted May 2016. Revisions submitted June 2016. Accepted for publication July 19, 2016.)

Key words: glioblastoma; genomic profiling; molecularly targeted therapy; radiation; surgery; temozolomide; tumor-treating fields (TTFields)

Digital Object Identifier: 10.1188/16.CJON.S1.2-8

Glioblastoma (GBM) is the most common primary malignant brain tumor, comprising 16% of all primary brain and central nervous system neoplasms (Thakkar et al., 2014). The average age-adjusted incidence rate is 3.2 per 100,000 population (Ostrom et al., 2015; Ostrom, Gittleman, et al., 2014). Although GBMs occur almost exclusively in the brain, they can also appear in the brain stem, cerebellum, and spinal cord. Sixty-one percent of all primary gliomas occur in the four lobes of the brain: frontal (25%), temporal (20%), parietal (13%), and occipital (3%) (American Association of Neuroscience Nurses [AANN], 2014). Originally, GBMs were thought to be derived solely from glial cells; however, evidence suggests that they may arise from multiple cell types with neural stem cell-like properties. These cells are at multiple stages of differentiation from stem cell to neuron to glia, with phenotypic variations determined, in large part, by molecular alterations in signaling pathways rather than by differences in cell type of origin (Phillips et al., 2006).

GBMs present at a median age of 64 years (Thakkar et al., 2014) but can occur at any age, including childhood. Inci-

dence is slightly higher in men than women (1.6:1) and in Caucasians relative to other ethnicities (Ellor, Pagano-Young, & Avgeropoulos, 2014). GBMs can be classified as primary, or de novo, arising without a known precursor; or secondary, where a low-grade tumor transforms over time into GBM. A majority of GBMs are primary, and these patients tend to be older aged and have a poorer prognosis than patients with secondary GBMs (Wilson, Karajannis, & Harter, 2014).

As a result of genomic profiling and the Cancer Genome Atlas project (Parsons et al., 2008), more than 600 genes were sequenced from greater than 200 human tumor samples, which revealed the complicated genetic profile of GBM and established a set of three core signaling pathways that are commonly activated (i.e., the tumor protein p53 [p53] pathway, the receptor tyrosine kinase/Ras/phosphoinositide 3-kinase signaling pathway, and the retinoblastoma pathway). The majority of primary and secondary GBMs have alterations in these pathways, giving rise to uncontrolled cell proliferation and enhanced cell survival, while also allowing the tumor cell to escape from cell-cycle checkpoints, senescence, and apoptosis pathways (Chen, McKay, & Parada, 2012).

Molecular alterations or gene expression patterns have also been recognized between primary and secondary gliomas. Genetic alterations typical for primary GBM are epidermal growth factor receptor (EGFR) overexpression, phosphate and tensin homologue (PTEN) mutations, and loss of chromosome 10q. In secondary GBM, isocitrate dehydrogenase 1 (IDH1) mutations, p53 mutations, and chromosome 19q loss are frequently seen (Alifieris & Trafalis, 2015; Wilson et al., 2014; Young, Jamshidi, Davis, & Sherman, 2015). In addition, four GBM subtypes have been identified (i.e., classical, proneural, neural, and mesenchymal), each with distinctly different patterns of disease progression and survival outcomes. For a more detailed analysis of GBM signaling pathways and subtypes, readers are referred to Brennan et al., 2013; Verhaak et al., 2010; and Wang et al., 2015.

Methods to determine a patient's tumor subtype require an invasive biopsy or surgical resection to perform genomic analysis. Imaging genomics is an emerging science that explores associations between molecular profiles and radiologic features and may eventually serve as a noninvasive technique to determine genomic correlation, prediction, and identification (Moton, Elbanan, Zinn, & Colen, 2015). Molecular subtyping shows promise in identifying subsets that may be uniquely responsive to specific adjuvant therapies (Vitucci, Hayes, & Miller, 2011), and future therapies will likely be tailored to target these underlying molecular abnormalities.

Risk Factors

Efforts to identify specific associations of this disease with environmental and occupational exposure have largely been inconclusive and underpowered. Ionizing radiation is one of the few known risk factors to definitely show an increased risk of glioma development (Ellor et al., 2014). Radiation-induced GBM is typically seen years after therapeutic radiation indicated for another tumor or condition (Johnson et al., 2015). Other environmental exposures to vinyl chloride, pesticides, smoking, petroleum refining, and synthetic rubber manufacturing have been loosely associated with the development of gliomas. Electromagnetic fields, formaldehyde, and nonionizing radiation from cell phones have not been proven to lead to GBM (Alifieris & Trafalis, 2015). An increased risk of glioma development is seen in some specific genetic diseases, such as neurofibromatosis 1 and 2, tuberous sclerosis, Li-Fraumeni syndrome, retinoblastoma, and Turcot syndrome; however, less than 1% of patients with a glioma have a known hereditary disease (Ellor et al., 2014).

Clinical Presentation

The presentation of a patient with newly diagnosed GBM can vary greatly depending on the size and location of the tumor and the anatomic structures of the involved brain (Lobera, 2015; Young et al., 2015). Patients often present with symptoms of increased intracranial pressure, including headache and focal or progressive neurologic deficits. A seizure is the presenting symptom in as many as 25% of patients and can occur at a later stage of the disease in as many as

50% of patients (Perry et al., 2006; Schiff et al., 2015). The current standard of care for a patient who presents with seizures includes the use of antiepileptic drugs (AEDs), but the routine use of AEDs in patients without seizures is not recommended (Glantz et al., 2000; Perry et al., 2006). Many patients are prescribed corticosteroids at diagnosis to help control vasogenic edema and alleviate accompanying signs and symptoms.

Initial diagnostic imaging may include a computed tomography (CT) or magnetic resonance imaging (MRI) scan. On MRI, nearly all GBMs enhance with gadolinium contrast and show an irregularly shaped mass with a dense ring of enhancement and hypointense center of necrosis. Necrosis is a hallmark feature of GBM, and presence of necrosis is required for a brain tumor to be grade IV or to be classified as a GBM on the World Health Organization classification system (AANN, 2014). Surrounding vasogenic edema (which may cause a mass effect), hemorrhage, and ventricular distortion or displacement may also be present on diagnostic imaging (Ellor et al., 2014; Johnson et al., 2015).

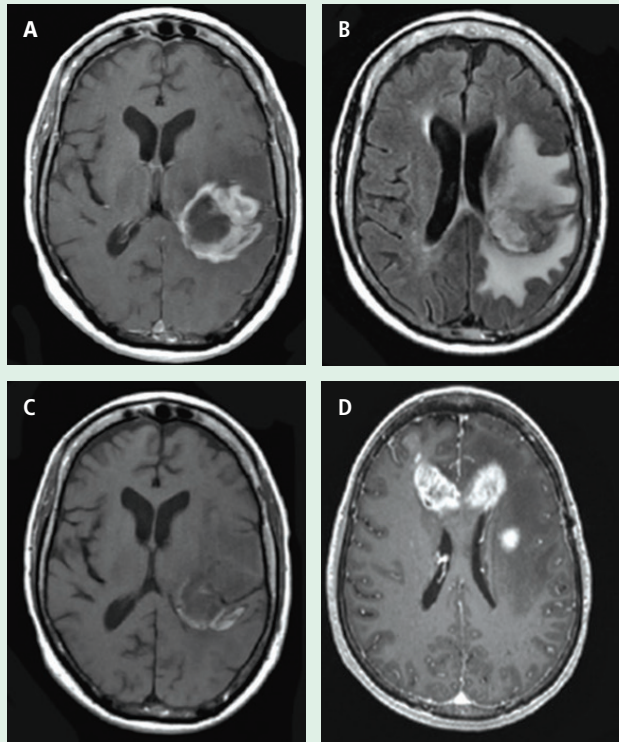
In about 13% of cases, GBM may present as multifocal (greater than two lesions including leptomeningeal dissemination), distant (second lesion noncontiguous with primary lesion), or diffuse disease, and it has been well established that microscopic tumor infiltration usually extends past visualized signal abnormality on MRI (Chamberlain, 2011; Johnson et al., 2015). Figure 1 displays radiographic features of GBM on MRI.

Treatment

Treatment of newly diagnosed GBM requires a multidisciplinary approach. Current standard therapy includes maximal safe surgical resection, followed by concurrent radiation with temozolomide (TMZ) (Temodar[®]), an oral alkylating chemotherapy agent, and then adjuvant chemotherapy with TMZ (National Comprehensive Cancer Network [NCCN], 2015). Extensive and complete surgical resection of GBM is difficult because these tumors are frequently invasive and are often in eloquent areas of the brain, including areas that control speech, motor function, and the senses. Because of the high degree of invasiveness, radical resection of the primary tumor mass is not curative, and infiltrating tumor cells invariably remain within the surrounding brain, leading to later disease progression or recurrence (Wilson et al., 2014).

Multiple studies have demonstrated the importance of aggressive surgical resection when possible, with trends toward better outcomes in those patients with a greater extent of resection (Kuhnt et al., 2011; Roder et al., 2014). Statistically significant associations between greater extent of resection and longer progression-free survival (PFS) and overall survival (OS) have been seen in several studies (Keles, Anderson, & Berger, 1999; Lacroix et al., 2001; Mukherjee & Quiñones-Hinojosa, 2011; Stummer et al., 2006). Improvements in surgical and preoperative mapping techniques have made it possible to achieve more extensive resection while preserving function and quality of life (Mukherjee & Quiñones-Hinojosa, 2011).

The use of functional MRI and diffusion tensor imaging (DTI) in preoperative planning, as well as ultrasound,



A—T1 post-gadolinium contrast with dense rim enhancement; B—axial flair showing extensive vasogenic edema causing mass effect on the left lateral ventricle; C—T1 pre-gadolinium showing hemorrhage (white areas) along posterior lateral margin of tumor; D—multifocal bihemispheric disease

FIGURE 1. Radiographic Features of Glioblastoma on Magnetic Resonance Imaging

Note. Images used with permission.

and higher performance status conferring longer survival. Tumors greater than 5–6 cm and those that cross the midline have been associated with negative outcomes (Ellor et al., 2014). Supratentorial (cerebrum) and cerebellar tumors, which are more amenable to surgical treatment, carry a better prognosis than tumors in the brainstem or diencephalon (Walid, 2008). An analysis by Johnson and O'Neill (2012) demonstrated a statistically significant improvement in OS since the onset of aggressive multimodality treatment.

Chemoradiation

Following optimal surgical resection, the patient commonly waits as many as four weeks for the craniotomy wound to heal before starting therapy. Postoperative radiation therapy (RT) alone was standard treatment until 2005, when the results of a pivotal phase III trial changed the standard of care for GBM. This trial confirmed that external beam RT with concomitant TMZ chemotherapy (known as the Stupp regimen) was more effective than RT alone (Stupp et al., 2005). Patients who received TMZ plus RT had a median survival of 14.6 months versus 12.1 months with RT alone. The survival advantage remained because the TMZ plus RT cohort had a higher proportion of long-term survivors than the RT alone group with 27% versus 11% at two years and 10% versus 2% at five years, respectively (Stupp et al., 2009). The analysis of this trial also led to the identification of another strong predictor of patient-related outcomes: the methylation of the *MGMT* gene, located on chromosome 10q26. *MGMT* codes for an enzyme involved with DNA repair. Patients who have methylated (not activated) *MGMT* exhibit compromised DNA repair. When the *MGMT* enzyme is activated, it can interfere with the effects of treatment. RT and alkylating chemotherapy exert their therapeutic effects by causing DNA damage and cytotoxicity and triggering apoptosis. Therefore, the expression of methylated *MGMT* is beneficial for patients undergoing TMZ chemotherapy and RT. In the trial by Stupp et al. (2009), methylation of *MGMT* was a strong predictor of better outcomes from TMZ treatment.

Historically, whole-brain RT (WBRT) was used in the treatment of newly diagnosed GBM, but multiple potential long-term complications of WBRT exist, including endocrinopathy, neurocognitive toxicity, and RT-induced leukoencephalopathy. These serious complications have led to research to explore the use of involved field RT (IFRT) to minimize toxicity (Shih & Batchelor, 2016). IFRT delivers external beam RT to the tumor with a 2–3 cm margin, which is based on the observation that, following RT, GBM recurs within 2 cm of the original tumor site in 80%–90% of cases (Narayana et al., 2006). Multiple studies in the early 1970s confirmed that IFRT had similar or slightly improved survival advantage over WBRT, with less normal tissue damage within the RT field (Barani & Larson, 2015).

RT using three-dimensional conformal beam or intensity-modulated RT is now the standard of care (Chao, Perez, Brady, & Marinetti, 2011). The typical total dose delivered is 60 Gy, in 1.8–2 Gy fractions administered five days per week for six weeks. A clear survival advantage has been demonstrated with postoperative RT doses to 60 Gy, but dose escalation

CT scans, and MRI with direct stimulation during surgery, has allowed for multimodal neuronavigation and the integration of patient-specific anatomic and functional data. Despite these technologies, differentiating between normal brain and residual tumor continues to be a major challenge, and the use of 5-aminolevulinic acid (5-ALA) dye for fluorescence guidance has been found to be more effective than conventional neuronavigation-guided surgery alone (Zhao et al., 2013). However, a Cochrane review found only low to very low-quality evidence that image-guided surgery using 5-ALA, intra-operative MRI, or DTI neuronavigation increased the proportion of patients with high-grade glioma that have a complete tumor resection on postoperative MRI (Barone, Lawrie, & Hart, 2014). Other limitations of these novel technologies include cost and the need for specialized equipment, operators, and surgery suites. Further studies are needed to clarify clinical benefits before they are established as standard of care for all patients with GBM.

Even with advances in surgical resection, the prognosis for patients with GBM remains poor, with a median survival of 15 months (Thakkar et al., 2014). Aside from extent of surgical resection, other factors have been associated with increased OS. Patient age and Karnofsky Performance Status are widely recognized as prognostic factors, with lower age

beyond this has resulted in increased toxicity without additional survival benefits (Barani & Larson, 2015).

To improve local control and limit toxicity to normal brain tissue, other techniques have been investigated, including iodine-125 brachytherapy, radioimmunotherapy, stereotactic radiosurgery, and hyperfractionation; however, these have not resulted in a significant survival advantage for newly diagnosed patients (Barani & Larson, 2015).

Concurrent with RT, TMZ is typically given at a dose of 75 mg/m² daily for six weeks, followed by a rest period of about one month after RT is completed. When restarted, TMZ is dosed at 150 mg/m² daily for five days for the first month (usually days 1–5 of 28). If tolerated, the dose is escalated up to 200 mg/m² for five consecutive days per month for the remainder of therapy. In the Stupp regimen, TMZ was administered for six months after RT. In common practice, many physicians continue TMZ cycles for 12–18 months, but no definitive data demonstrate that prolonged TMZ regimens confer superior survival (Johnson et al., 2015).

In October 2015, Optune[®], the device delivering tumor-treating fields (TTFields), received approval from the U.S. Food and Drug Administration (FDA) as a treatment alongside TMZ for adults with newly diagnosed supratentorial GBM, following surgery and standard-of-care treatment. Optune uses TTFields, an innovative technology that delivers low-intensity, intermediate-frequency alternating electrical fields to tumor cells. TTFields interrupt cell division, causing apoptosis, or cell death. This expanded indication by the FDA followed interim analysis data from 315 patients randomized to Optune plus TMZ versus TMZ alone in the adjuvant setting. Optune plus TMZ demonstrated superior PFS of 7.1 months versus 4 months with TMZ alone, as well as superior OS of 20.5 months versus 15.6 months with TMZ alone (Stupp et al., 2015).

Disease Recurrence

Despite maximal initial resection and multimodality therapy, about 70% of GBM patients will experience disease progression within one year of diagnosis (Stupp et al., 2005), with less than 5% of patients surviving five years after diagnosis (Ostrom, Bauchet, et al., 2014). Re-resection is an option for some patients, and surgical debulking can alleviate mass effect and symptoms, such as seizures, speech, and motor deficits, frequently seen at recurrence. Repeat surgery may be required to confirm a diagnosis of tumor recurrence versus pseudoprogression or radiation necrosis and may also provide tissue for molecular testing to identify potential new targeted agents (Brandes, Bartolotti, & Franceschi, 2013). Opinion varies as to whether repeat surgery enhances OS. Some evidence exists that greater extent of resection at recurrence is associated with improved survival (Bloch et al., 2012; McGirt et al., 2009); however, other studies have not found an absolute benefit in terms of survival (Brandes et al., 2013; Franceschi et al., 2015).

Additional radiation may be possible for some patients, but tolerance of healthy brain tissue to radiation is limited because of the increased risk of radiation necrosis. A wide variety of radiation techniques, including brachytherapy,

gamma knife, and stereotactic radiosurgery, may be used for treatment of recurrent disease (Davis & Stoiber, 2011).

Upon recurrence of GBM, chemotherapy and corticosteroids may be used to palliate symptoms and improve quality of life, but objective response rates are dismal, and time to progression for standard cytotoxic agents is only three to six months (Franceschi et al., 2009). Rechallenging with TMZ may be an option, and other agents, such as carboplatin (Paraplatin[®]), etoposide (Toposar[®]), irinotecan (Camptosar[®]), and nitrosourea-based chemotherapy, may be tried as single agents or in regimens. Bevacizumab (Avastin[®]) is a humanized monoclonal antibody that targets vascular endothelial growth factor, a protein necessary for angiogenesis. It was approved in 2009 for recurrent GBM disease. Trials have demonstrated superior PFS; however, meaningful improvements in OS have not been seen (Cohen, Shen, Keegan, & Pazdur, 2009). Bevacizumab has also been shown to reduce vascular permeability and edema, improve oxygenation, and reduce radiation necrosis when administered with RT (Niyazi et al., 2016). However, it can cause potentially life-threatening events, such as hemorrhage, blood clots, and bowel perforation (Salacz, Watson, & Schomas, 2011; Taal et al., 2014).

Optune was initially approved by the FDA in 2011 for use in recurrent GBM as monotherapy. Optune is indicated following histologically or radiologically confirmed recurrence in the supratentorial region of the brain after receiving chemotherapy, and is intended as an alternative to standard medical therapy for GBM after surgical and radiation options have been exhausted (Novocure, 2016). A randomized clinical trial versus standard chemotherapy demonstrated

Peritumoral edema requiring long-term corticosteroid use

- Impaired glucose tolerance
- Insomnia
- Steroid myopathy
- Infection potential
- Weight gain
- Gastrointestinal irritation and bleeding
- Behavioral changes and irritability
- Taste changes

Venous thromboembolism

- Pulmonary embolism
- Deep vein thrombosis

Seizures

- Risk of seizures is related to tumor pathology and location.
- Risk is highest with cortical tumors, particularly those located in the motor cortex and when meninges are involved.

Cognitive dysfunction

- Poor short-term memory
- Personality changes
- Loss of executive function
- Decreased psychomotor speed
- Depression

FIGURE 2. Common Glioblastoma-Related Complications

Note. Based on information from Lacy et al., 2012; Pruitt, 2015; Shah & Morrison, 2013.

Implications for Practice

- ▶ Glioblastoma is a cancer with a poor prognosis, and tumors generally recur after standard multimodal treatments.
- ▶ Genomic profiling of glioblastoma tumors has identified potential new treatment options that target molecular receptors and signaling pathways.
- ▶ Aggressive symptom management and honest discussion of patient goals and wishes offer patients hope for enhanced survival and improved quality of life.

equivalent survival with fewer side effects and significantly less gastrointestinal, hematologic, and infectious adverse events (Stupp et al., 2012). The lack of significant side effects from the device, primarily scalp irritation from the arrays (electrodes), makes TTFields an attractive treatment option. In addition, patients reported improved quality-of-life measures, such as cognitive and emotional functioning, over patients receiving chemotherapy. Use of Optune for delivery of TTFields has been included as an option in the NCCN guidelines for recurrent GBM (Davis, 2013; NCCN, 2015). TTFields remains a compelling treatment option for maintenance therapy in recurrent disease.

Clinical Trials

Cellular regulatory pathways with tyrosine kinase and signal transduction inhibitors are being investigated within clinical trials. Immunotherapy research is ongoing, with the use of monoclonal antibodies and vaccines. An immunotherapy vaccine targeting EGFR variant III, rindopepimut (Rintega[®]), has been tested in clinical trials in patients with newly diagnosed GBM but failed to confer any survival benefit, and the clinical trial was terminated (Celldex Therapeutics, Inc., 2016). In general, immune checkpoint blockade is a promising target in recurrent GBM. Agents targeting programmed cell death protein 1 (PD-1) receptors, its ligand PD-L1, and cytotoxic T-lymphocyte-associated antigen 4 (CTLA4) receptors have been shown to have antitumor activity in other cancers, such as melanoma; therefore, research in patients with recurrent GBM is underway. Manipulation of the blood-brain barrier to enhance targeted delivery of drug is also being studied. Hopefully, the results of these trials and other novel approaches may lead to increased survival and enhanced quality of life for patients with GBM.

Supportive Care

GBMs are very aggressive tumors, accompanied by an array of complications related to the underlying disease and treatment. Recognition and management of these symptoms is essential to optimize quality of life. Many side effects related to treatment (e.g., chemotherapy-induced myelosuppression, nausea, fatigue, constipation) and early radiation-related effects (e.g., alopecia, dysgeusia, anorexia) are not unique to the GBM population and can generally be

medically managed. Other symptoms frequently occurring in patients with GBM are listed in Figure 2. For a review on specific management of GBM symptoms, the reader is referred to AANN, 2014; Davis & Stoiber, 2011; Lacy, Saadati, & Yu, 2012; Pruitt, 2015; and Shah & Morrison, 2013.

Conclusion

Palliative care should be initiated at diagnosis, with ongoing sensitive and empathetic discussions concerning goals of care and wishes throughout the continuum of care. Honest discussions about prognosis and vigilant attention to symptom management are necessary to achieve the overarching goal of maintaining the patient's quality of life as long as possible (Pruitt, 2015). Effective symptom management, a focus on improved quality of life, and novel therapeutic treatment approaches may offer renewed hope to patients with GBM and their families.

References

- Aliferis, C., & Trafalis, D.T. (2015). Glioblastoma multiforme: Pathogenesis and treatment. *Pharmacology and Therapeutics*, 152, 63–82. doi:10.1016/j.pharmthera.2015.05.005
- American Association of Neuroscience Nurses. (2014). *Care of the adult patient with a brain tumor*. Retrieved from <http://www.abta.org/resources/health-care-provider/final-adult-clinical-practice.pdf>
- Barani, I.J., & Larson, D.A. (2015). Radiation therapy of glioblastoma. *Cancer Treatment and Research*, 163, 49–73. doi:10.1007/978-3-319-12048-5_4
- Barone, D.G., Lawrie, T.A., & Hart, M.G. (2014). Image guided surgery for the resection of brain tumours. *Cochrane Database of Systematic Reviews*, 28, CD009685. doi:10.1002/14651858.CD009685.pub2
- Bloch, O., Han, S.J., Cha, S., Sun, M.Z., Aghi, M.K., McDermott, M.W., . . . Parsa, A.T. (2012). Impact of extent of resection for recurrent glioblastoma on overall survival. *Journal of Neurosurgery*, 117, 1032–1038. doi:10.3171/2012.9.JNS12504
- Brandes, A.A., Bartolotti, M., & Francheschi, E. (2013). Second surgery for recurrent glioblastoma: Advantages and pitfalls. *Expert Review of Anticancer Therapy*, 13, 583–587. doi:10.1586/era.13.32
- Brennan, C.W., Verhaak, R.G., McKenna, A., Campos, B., Nounshahr, H., Salama, S.R., . . . Chin, L. (2013). The somatic genomic landscape of glioblastoma. *Cell*, 155, 462–477. doi:10.1016/j.cell.2013.09.034
- Celldex Therapeutics, Inc. (2016). *Data safety and monitoring board recommends Celldex's phase 3 study of RINTEGA[®] (rindopepimut) in newly diagnosed glioblastoma be discontinued as it is unlikely to meet primary overall survival endpoint in patients with minimal residual disease* [Press release]. Retrieved from <http://ir.celldex.com/releasedetail.cfm?ReleaseID=959021>
- Chamberlain, M.C. (2011). Radiographic patterns of relapse in glioblastoma. *Journal of Neuro-Oncology*, 101, 319–323. doi:10.1007/s11060-010-0251-4
- Chao, K.S.C., Perez, C.A., Brady, L.W., & Marinetti, T. (2011). Management of adult central nervous system tumors. In K.S.C. Chao, C.A. Perez, & L.W. Brady (Eds.), *Radiation oncology:*

- Management decisions* (3rd ed., pp. 146–191). Philadelphia, PA: Lippincott Williams and Wilkins.
- Chen, J., McKay, R.M., & Parada, L.F. (2012). Malignant glioma: Lesions from genomics, mouse models, and stem cells. *Cell*, *149*, 36–47. doi:10.1016/j.cell.2012.03.009
- Cohen, M.H., Shen, Y.L., Keegan, P., & Pazdur, R. (2009). FDA drug approval summary: Bevacizumab (Avastin) as treatment of recurrent glioblastoma multiforme. *Oncologist*, *14*, 1131–1138. doi:10.1634/theoncologist.2009-0121
- Davis, M.E. (2013). Tumor treating fields—An emerging cancer treatment modality. *Clinical Journal of Oncology Nursing*, *17*, 441–443. doi:10.1188/13.CJON.441-443
- Davis, M.E., & Stoiber, A.M. (2011). Glioblastoma multiforme: Enhancing survival and quality of life. *Clinical Journal of Oncology Nursing*, *15*, 291–297. doi:10.1188/11.CJON.291-297
- Ellor, S.V., Pagano-Young, T.A., & Avgeropoulos, N.G. (2014). Glioblastoma: Background, standard treatment paradigms, and supportive care considerations. *Journal of Law, Medicine, and Ethics*, *42*, 171–182. doi:10.1111/jlme.12133
- Franceschi, E., Bartolotti, M., Tosoni, A., Bartolini, S., Sturiale, C., Fioravanti, A., . . . Brandes, A.A. (2015). The effect of reoperation on survival in patients with recurrent glioblastoma. *Anticancer Research*, *35*, 1743–1748.
- Franceschi, E., Tosoni, A., Bartolini, S., Mazzocchi, V., Fioravanti, A., & Brandes, A.A. (2009). Treatment options for recurrent glioblastoma: Pitfalls and future trends. *Expert Review of Anticancer Therapy*, *9*, 613–619. doi:10.1586/era.09.23
- Glantz, M.J., Cole, B.F., Forsyth, P.A., Recht, L.D., Wen, P.Y., Chamberlain, M.C., . . . Cairncross, J.G. (2000). Practice parameter: Anticonvulsant prophylaxis in patients with newly diagnosed brain tumors. Report of the Quality Standards Subcommittee of the American Academy of Neurology. *Neurology*, *54*, 1886–1893. doi:10.1212/WNL.54.10.1886
- Johnson, D.R., Fogh, S.E., Giannini, C., Kaufmann, T.J., Raghunathan, A., Theodosopoulos, P.V., & Clarke, J.L. (2015). Case-based review: Newly diagnosed glioblastoma. *Neuro-Oncology Practice*, *2*, 106–121. doi:10.1093/nop/npv020
- Johnson, D.R., & O'Neill, B.P. (2012). Glioblastoma survival in the United States before and during the temozolomide era. *Journal of Neuro-Oncology*, *107*, 359–364. doi:10.1007/s11060-011-0749-4
- Keles, G.E., Anderson B., & Berger, M.S. (1999). The effect of extent of resection on time to tumor progression and survival in patients with glioblastoma multiforme of the cerebral hemisphere. *Surgical Neurology*, *52*, 371–379. doi:10.1016/S0090-3019(99)00103-2
- Kuhnt, D., Becker, A., Ganslandt, O., Bauer, M., Buchfelder, M., & Nimsky, C. (2011). Correlation of the extent of tumor volume resection and patient survival in surgery of glioblastoma multiforme with high-field intraoperative MRI guidance. *Neuro-Oncology*, *13*, 1339–1348. doi:10.1093/neuonc/nor133
- Lacroix, M., Abi-Said, D., Fourny, D.R., Gokaslan, Z.L., Shi, W., DeMonte, F., . . . Sawaya, R. (2001). A multivariate analysis of 416 patients with glioblastoma multiforme: Prognosis, extent of resection, and survival. *Journal Neurosurgery*, *95*, 190–198.
- Lacy, J., Saadati, H., & Yu, J.B. (2012). Complications of brain tumors and their treatment. *Hematology/Oncology Clinics of North America*, *26*, 779–796. doi:10.1016/j.hoc.2012.04.007
- Lobera, A. (2015). Imaging in glioblastoma multiforme. Retrieved from <http://emedicine.medscape.com/article/340870-overview>
- McGirt, M.J., Chaichana, K.L., Gathinji, M., Attenello, F.J., Than, K., Olivi, A., . . . Quiñones-Hinojosa, A.R. (2009). Independent association of extent of resection with survival in patients with malignant brain astrocytoma. *Journal of Neurosurgery*, *110*, 156–162. doi:10.3171/2008.4.17536
- Moton, S., Elbanan, M., Zinn, P.O., & Colen, R.R. (2015). Imaging genomics of glioblastoma: Biology, biomarkers, and breakthroughs. *Topics in Magnetic Resonance Imaging*, *24*, 155–163. doi:10.1097/RMR.0000000000000052
- Mukherjee, D., & Quiñones-Hinojosa, A. (2011). Impact of extent of resection on outcomes in patients with high-grade gliomas. In M.A. Hayat (Ed.), *Tumors of the central nervous system* (Vol. 2, pp. 173–179). San Francisco, CA: Springer.
- Narayana, A., Yamada, J., Berry, S., Shah, P., Hunt, M., Gutin, P.H., & Leibel, S.A. (2006). Intensity-modulated radiotherapy in high-grade gliomas: Clinical and dosimetric results. *International Journal of Radiation Oncology Biology Physics*, *64*, 892–897. doi:10.1016/j.ijrobp.2005.05.067
- National Comprehensive Cancer Network. (2015). *Clinical Practice Guidelines in Oncology: Central nervous system cancers* [v.1.2015]. Retrieved from https://www.nccn.org/professionals/physician_gls/pdf/cns.pdf
- Niyazi, M., Harter, P.N., Hattingen, E., Rottler, M., von Baumgarten, L., Proescholdt, M., . . . Mittelbronn, M. (2016). Bevacizumab and radiotherapy for the treatment of glioblastoma: Brothers in arms or unholy alliance? *Oncotarget*, *7*, 2313–2328. doi:10.18632/oncotarget.6320
- Novocure. (2016). *Optune®: Instructions for use*. Retrieved from https://www.optune.com/Content/pdfs/Optune_IFU_8.5x11.pdf
- Ostrom, Q.T., Bauchet, L., Davis, F.G., Deltour, I., Fischer, J.L., Langer, C.E., . . . Barnholtz-Sloan, J.S. (2014). The epidemiology of glioma in adults: A “state of the science” review. *Neuro-Oncology*, *16*, 896–913. doi:10.1093/neuonc/nou087
- Ostrom, Q.T., Gittleman, H., Fulop, J., Liu, M., Blanda, R., Kromer, C., . . . Barnholtz-Sloan, J.S. (2015). CBTRUS statistical report: Primary brain and central nervous system tumors diagnosed in the United States in 2008–2012. *Neuro-Oncology*, *17*(Suppl. 4), iv1–v62. doi:10.1093/neuonc/nov189
- Ostrom, Q.T., Gittleman, H., Liao, P., Rouse, C., Chen, Y., Dowlings, J., . . . Barnholtz-Sloan, J. (2014). CBTRUS statistical report: Primary brain and central nervous system tumors diagnosed in the United States in 2007–2011. *Neuro-Oncology*, *16*(Suppl. 4), iv1–63. doi:10.1093/neuonc/nou223
- Parsons, D.W., Jones, S., Zhang, X., Lin, J.C., Leary, R.J., Angenendt, P., . . . Kinzler, K.W. (2008). An integrated genomic analysis of human glioblastoma multiforme. *Science*, *321*, 1807–1812. doi:10.1126/science.1164382
- Perry, J., Zinman, L., Chambers, A., Spithoff, K., Lloyd, N., & Laperriere, N. (2006). The use of prophylactic anticonvulsants in patients with brain tumours—A systematic review. *Current Oncology*, *13*, 222–229.
- Phillips, H.S., Kharbanda, S., Chen, R., Forrester, W.F., Soriano, R.H., Wu, T.D., . . . Aldape, K. (2006). Molecular subclasses of high-grade glioma predict prognosis, delineate a pattern of disease progression, and resemble stages in neurogenesis. *Cancer Cell*, *9*, 157–173. doi:10.1016/j.ccr.2006.02.019
- Pruitt, A.A. (2015). Medical management of patients with brain tumors. *Continuum: Lifelong Learning in Neurology*, *21*, 314–331. doi:10.1212/01.con.0000464172.50638.21
- Roder, C., Bisdas, S., Ebner, F.H., Honegger, J., Naegle, T., Ernemann, U., & Tatagiba, M. (2014). Maximizing the extent

- of resection and survival benefit of patients in glioblastoma surgery: High-field iMRI versus conventional and 5-ALA-assisted surgery. *European Journal of Surgical Oncology*, *40*, 297–304. doi:10.1016/j.ejso.2013.11.022
- Salacz, M.E., Watson, K.R., & Schomas, D.A. (2011). Glioblastoma: Part I. Current state of affairs. *Missouri Medicine*, *108*, 187–194.
- Schiff, D., Lee, E.Q., Nayak, L., Norden, A.D., Reardon, D.A., & Wen, P. (2015). Medical management of brain tumors and the sequelae of treatment. *Neuro-Oncology*, *17*, 488–504. doi:10.1093/neuonc/nou304
- Shah, U., & Morrison, T. (2013). A review of the symptomatic management of malignant gliomas in adults. *Journal of the National Comprehensive Cancer Network*, *11*, 424–429.
- Shih, H.A., & Batchelor, T. (2016). Adjuvant radiation therapy for high-grade gliomas. Retrieved from <http://www.uptodate.com/contents/adjuvant-radiation-therapy-for-high-grade-gliomas#H3>
- Stummer, W., Pichlmeier, U., Meinel, T., Wiestler, O.D., Zanella, F., & Reulen, H.J. (2006). Fluorescence-guided surgery with 5-aminolevulinic acid for resection of malignant glioma: A randomized controlled multicentre phase III trial. *Lancet Oncology*, *7*, 392–401. doi:10.1016/S1470-2045(06)70665-9
- Stupp, R., Hegi, M.E., Mason, W.P., van den Bent, M.J., Taphoorn, M.J., Janzer, R.C., . . . Mirimanoff, R.O. (2009). Effects of radiotherapy with concomitant and adjuvant temozolomide versus radiotherapy alone on survival in glioblastoma in a randomised phase III study: 5-year analysis of the EORTC-NCIC trial. *Lancet Oncology*, *10*, 459–466. doi:10.1016/S1470-2045(09)70025-7
- Stupp, R., Mason, W.P., van den Bent, M.J., Weller, M., Fisher, B., Taphoorn, M.J., . . . Mirimanoff, R.O. (2005). Radiotherapy plus concomitant and adjuvant temozolomide for glioblastoma. *New England Journal of Medicine*, *352*, 987–996. doi:10.1056/NEJMoa043330
- Stupp, R., Taillibert, S., Kanner, A.A., Kesari, S., Steinberg, D.M., Toms, S.A., . . . Ram, Z. (2015). Maintenance therapy with tumor-treating fields plus temozolomide vs temozolomide alone for glioblastoma: A randomized clinical trial. *JAMA*, *314*, 2535–2543. doi:10.1001/jama.2015.16669
- Stupp, R., Wong, E.T., Kanner, A.A., Steinberg, D., Engelhard, H., Heidecke, V., . . . Gutin, P.H. (2012). NovoTTF-100A versus physician's choice chemotherapy in recurrent glioblastoma: A randomized phase III trial of a novel treatment modality. *European Journal of Cancer*, *48*, 2192–2202. doi:10.1016/j.ejca.2012.04.011
- Taal, W., Oosterkamp, H.M., Walenkamp, A.M., Dubbink, H.J., Beerepoot, L.V., Hanse, M.C., . . . van den Bent, M.J. (2014). Single-agent bevacizumab or lomustine versus a combination of bevacizumab plus lomustine in patients with recurrent glioblastoma (BELOB trial): A randomised controlled phase 2 trial. *Lancet Oncology*, *15*, 943–953. doi:10.1016/S1470-2045(14)70314-6
- Thakkar, J.P., Dolecek, T.A., Horbinski, C., Ostrom, Q.T., Lightner, D.D., Barnholtz-Sloan, J.S., & Villano, J.L. (2014). Epidemiologic and molecular prognostic review of glioblastoma. *Cancer Epidemiology, Biomarkers and Prevention*, *23*, 1985–1996. doi:10.1158/1055-9965.EPI-14-0275
- Verhaak, R.G., Hoadley, K.A., Purdom, E., Wang, V., Qi, Y., Wilkerson, M.D., . . . Hayes, D.N. (2010). Integrated genomic analysis identifies clinically relevant subtypes of glioblastoma characterized by abnormalities in PDGFRA, IDH1, EGFR, and NF1. *Cancer Cell*, *17*, 98–110. doi:10.1016/j.ccr.2009.12.020
- Vitucci, M., Hayes, D.N., & Miller C.R. (2011). Gene expression profiling of gliomas: Merging genomic and histopathological classification for personalised therapy. *British Journal of Cancer*, *104*, 545–553. doi:10.1038/sj.bjc.6606031
- Walid, M.S. (2008). Prognostic factors for long-term survival after glioblastoma. *Permanente Journal*, *12*(4), 45–48. doi:10.7812/TPP/08-027
- Wang, H., Xu, T., Jiang, Y., Xu, H., Yan, Y., Fu, D., & Chen, J. (2015). The challenges and the promise of molecular targeted therapy in malignant gliomas. *Neoplasia*, *17*, 239–255. doi:10.1016/j.neo.2015.02.002
- Wilson, T.A., Karajannis, M.A., & Harter, D.H. (2014). Glioblastoma multiforme: State of the art and future therapeutics. *Surgical Neurology International*, *5*, 64–62. doi:10.4103/2152-7806.132138
- Young, R.M., Jamshidi, A., Davis, G., & Sherman, J.H. (2015). Current trends in the surgical management and treatment of adult glioblastoma. *Annals of Translational Medicine*, *3*, 121.
- Zhao, S., Wu, J., Wang, C., Liu, H., Dong, X., Shi, C., . . . Li, H. (2013). Intraoperative fluorescence-guided resection of high-grade malignant gliomas using 5-aminolevulinic acid-induced porphyrins: A systematic review and meta-analysis of prospective studies. *PLOS One*, *8*, e63682. doi:10.1371/journal.pone.0063682