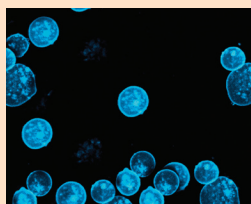


Impact of an Alert System on Quality Indicators in Patients With Acute Promyelocytic Leukemia

Lisa M. Blackburn, MS, RN, AOCNS®, Nicole Bauchmire, BSN, RN, OCN®, Sarah Bender, MS, RN, CNP, OCN®, Kelly Tomlinson-Pinkham, MSN, RN, OCN®, Scott Roberts, MS, BSN, RN, and Sherry Rosan, BSN, RN, OCN®



© vshivkova/iStock

Background: Acute promyelocytic leukemia (APL), once the most lethal form of adult acute leukemia, has become the most curable. The goal of early and well-managed treatment induction is to reduce the malignant burden of promyelocytes to below the cytologically detectable level.

Objectives: Oncology nurses who care for patients with APL need to be acutely aware of the basic differences in this disease from other forms of leukemia, including the two main complications for the newly diagnosed patient: disseminated intravascular coagulation and differentiation syndrome.

Methods: This article will briefly review APL and its associated presenting symptoms, prognosis, treatment, and complications.

Findings: These complications require immediate activation of expert staff and resources to protect critically ill patients with APL from associated morbidity and mortality.

Lisa M. Blackburn, MS, RN, AOCNS®, is a leukemia clinical nurse specialist, Nicole Bauchmire, BSN, RN, OCN®, is a staff nurse IV, Sarah Bender, MS, RN, CNP, OCN®, is a hematology-certified nurse practitioner, Kelly Tomlinson-Pinkham, MSN, RN, OCN®, is a nurse manager, Scott Roberts, MS, BSN, RN, is an assistant nurse manager, and Sherry Rosan, BSN, RN, OCN®, is a staff nurse, all in the Ohio State University Comprehensive Cancer Center at the Arthur G. James Cancer Hospital and Richard J. Solove Research Institute in Columbus. The authors take full responsibility for the content of the article. The authors did not receive honoraria for this work. The content of this article has been reviewed by independent peer reviewers to ensure that it is balanced, objective, and free from commercial bias. No financial relationships relevant to the content of this article have been disclosed by the authors, planners, independent peer reviewers, or editorial staff. Mention of specific products and opinions related to those products do not indicate or imply endorsement by the *Clinical Journal of Oncology Nursing* or the Oncology Nursing Society. Blackburn can be reached at lisa.blackburn@osumc.edu, with copy to editor at CJONEditor@ons.org. (Submitted October 2015. Revision submitted December 2015. Accepted for publication December 11, 2015.)

Key words: acute promyelocytic leukemia; disseminated intravascular coagulation; differentiation syndrome; fibrinogen; all-trans retinoic acid

Digital Object Identifier: 10.1188/16.CJON.523-527

Acute promyelocytic leukemia (APL), a subtype of acute myeloid leukemia (AML), was once considered the most fatal form of AML because of its significant propensity for bleeding and the subsequent high mortality rate associated with early hemorrhagic death (Coombs, Tavakkoli, & Tallman, 2015). However, advances in the understanding of the disease process and improvements in the available therapies since the 1980s have led to it being considered the most curable (Peterson, Trautman, Hoffner, & Zakrocki, 2013). APL makes up 5%–10% of all cases of AML (Peterson et al., 2013) and appears to be more common in patients of Latin American descent, representing about 20%–25% of AML cases in Latin countries (Ribeiro & Rego, 2006). In the United States, the incidence of APL diagnoses is estimated to be 600–800 cases per year. A diagnosis of APL is considered to be highly unlikely in children and is most commonly seen in adults in midlife. Cases are most commonly diagnosed in adults ranging from 20–50 years of age (Ribeiro & Rego, 2006).

A key characteristic of APL is the presence of atypical promyelocytes, both in the bone marrow and in the peripheral

blood. This disease is distinguished from other forms of AML by the cytogenetic translocation of the long arms of chromosomes 15 and 17 (Wang & Chen, 2008). One of the genes responsible, the promyelocyte leukemia, or *PML* gene, is on chromosome 15 and is thought to be responsible for apoptosis and tumor suppression. The other gene responsible, the retinoic acid receptor-alpha, or *RAR α* , is on chromosome 17 and is mostly responsible for myeloid differentiation. The translocation of genetic material that occurs between these two chromosomes creates a fusion between parts of the *PML* gene to parts of the *RAR α* gene. This chromosomal translocation of genetic material causes neither the *PML* nor the *RAR α* protein to act in its original capacity. Because of this morphology of chromosomes, blood cells cannot differentiate past the promyelocyte phase and, thereby, result in both the bone marrow and the peripheral blood being filled with promyelocytes (Peterson et al., 2013; Walker & Held-Warmkessel, 2010).

The clinical presentation of APL, like that of AML, can be nondescript, with many patients experiencing days to weeks of nonspecific symptoms followed by the occurrence of