

Hepatic Sinusoidal Obstruction Syndrome in Patients Undergoing Hematopoietic Stem Cell Transplant

Seth Eisenberg, RN, OCN®

Purpose/Objectives: To provide a comprehensive review of hepatic sinusoidal obstruction syndrome (HSOS) in patients receiving a hematopoietic stem cell transplant and to describe the implications for nursing care.

Data Sources: Published research articles, reviews, case reports, and books.

Data Synthesis: Disagreement exists regarding the precise cause of HSOS. Prevention and treatment strategies have emerged based on these causative theories. Few published resources are available for nursing assessment and intervention specific to HSOS, although symptom management strategies derived from other disease etiologies can be used successfully.

Conclusions: HSOS is a complex consequence of myeloablative chemoradiotherapy. Although the overall incidence is declining, research continues to explore better methods for prophylaxis and develop more efficacious treatment options.

Implications for Nursing: Nurses caring for patients receiving a hematopoietic stem cell transplant must comprehend the proposed etiologies for HSOS and be familiar with the manifestations of the syndrome. Symptom management requires a thorough understanding of affected organ systems.

Key Points . . .

- ▶ Hepatic sinusoidal obstruction syndrome (HSOS), also referred to as hepatic veno-occlusive disease, is a potentially life-threatening consequence of high-dose chemotherapy used in hematopoietic stem cell transplant that results in jaundice, weight gain, and painful hepatomegaly.
- ▶ HSOS can result in damage to the cardiovascular, pulmonary, renal, gastrointestinal, integumentary, and neurologic systems.
- ▶ Nurses need to understand the sequelae of hepatic damage and the rationale for current methods of preventing and treating these complications.
- ▶ Patients with HSOS require tremendous physical and psychosocial support.

Hepatic Anatomy and Physiology

The liver is a highly vascular organ that receives its blood supply from two sources: approximately 30% from the hepatic artery and 70% from the portal vein (Jakubik, Cockerham, Altmann, & Grossman, 2003). Blood is filtered through the sponge-like structure of the hepatic parenchyma before entering the hepatic vein and returning to the vena cava. The liver is responsible for a number of crucial physiologic functions (see Figure 1), and disruption of these functions produces many of the signs and symptoms associated with HSOS.

Seth Eisenberg, RN, OCN®, is the professional practice coordinator for infusion services at the Seattle Cancer Care Alliance ambulatory clinic in Washington. Mention of specific products and opinions related to those products do not indicate or imply endorsement by the Oncology Nursing Forum or the Oncology Nursing Society. No financial relationships to disclose. (Submitted September 2007. Accepted for publication October 18, 2007.)

Digital Object Identifier: 10.1188/08.ONF.385-397

Myeloablative hematopoietic stem cell transplant (HSCT) involves the administration of supralesional doses of chemotherapy with or without radiotherapy, followed by the infusion of peripheral blood stem cells, bone marrow, or umbilical cord blood. In addition to the expected hematologic toxicities, high-dose chemoradiotherapy can cause a potentially fatal liver condition referred to as hepatic sinusoidal obstruction syndrome (HSOS).

Goal for CNE Enrollees

To enhance nurses' knowledge regarding hepatic sinusoidal obstruction syndrome (HSOS).

Objectives for CNE Enrollees

1. Define HSOS and identify risk factors for patients.
2. Recognize the symptoms of HSOS.
3. Identify nursing measures to support patients with HSOS.

- Drug metabolism
- Removal of toxins
- Degradation of worn out erythrocytes
- Synthesis of albumin
- Synthesis of clotting proteins
- Storage of vitamins A, D, E, and K
- Detoxification of ammonia into urea

Figure 1. Functions of the Liver

Note. Based on information from Peck & Griffith, 1988; Tasota & Tate, 2000.

Hepatic Microanatomy

The portal triad is comprised of branches of the portal vein, hepatic artery, and bile duct and makes up the basic functional unit of the liver. Each triad can be subdivided into discrete hexagonal sections known as lobules centered around a terminal hepatic vein (see Figure 2). Within the lobules are smaller triangular areas called acini that are further divided into zones representing metabolic regions increasingly distant from the afferent blood supply and closer to the central vein (see Figure 3).

Rows of hepatocytes form thin hepatic cords separated by narrow cavities known as sinusoids. Blood from the portal vein and hepatic artery mixes in the sinusoids and empties through the central vein before returning to the vena cava. Sinusoids are lined by fragile sinusoidal endothelial cells (SECs) that lack a basement membrane. The sinusoids are fenestrated, allowing plasma to flow freely into the space of Disse (see Figure 4). A delicate network of collagen fibers supports the SECs. Because of the fenestrations and the lack of a basement membrane, albumin flows outward between the hepatocytes and sinusoids. The sinusoids also are lined by phagocytic Kupffer cells that aid in the removal of pathogens.

A Controversial Syndrome

Disagreement exists regarding the name, pathophysiology, defining criteria for, and treatment of HSOS. The syndrome historically been known as hepatic veno-occlusive disease (VOD), a name that dates back a half century and was first applied to hepatic failure associated with the ingestion of Seneccio tea, which contains pyrrolizidine alkaloids (Bras, Berry, & Gyorgy, 1957). This hepatic toxicity resulted in a syndrome of painful hepatomegaly, fluid retention, increased serum bilirubin, and ascites. By the late 1970s, Shulman and colleagues noted a similar syndrome in patients who had received bone marrow transplants with high-dose chemoradiotherapy (McDonald, Sharma, Matthews, Shulman, & Thomas, 1984; Shulman et al., 1980). Autopsies revealed partial-to-complete obliteration of the terminal hepatic venules with central necrosis and damage to the sinusoids. Deposition of fibrin and factor VIII subsequently was identified by Bearman (1995). The presence of hypercoagulability with fibrin deposition in the terminal hepatic venules provided the rationale for keeping the name VOD, and has been the impetus for anticoagulant-based prophylactic and treatment strategies.

The exact cause of liver damage following myeloablative therapy is subject to debate. In 1994, researchers noted that occlusion of the hepatic venules by fibrinous debris was not always present in autopsies of patients who had died from HSOS (Shulman, Fisher, Schoch, Henne, & McDonald, 1994). More recent research suggests that damage occurs first in the sinu-

soids rather than “downstream” in the terminal hepatic venules and, when present, venular occlusion is a consequence rather than a cause of the syndrome (DeLeve, Shulman, & McDonald, 2002). This theory would help explain why thrombolytic-based therapy has been inconsistently effective (DeLeve et al., 2003; Imran, Tleyjeh, Zirakzadeh, Rodriguez, & Khan, 2006).

In light of the newer information, DeLeve et al. (2002) proposed renaming the condition to HSOS, reflecting the theory that the syndrome arises in the sinusoids and not in the veins. Other researchers have supported this change in nomenclature (Helmy, 2006; Wingard, Nichols, & McDonald, 2004), although many clinicians continue to embrace the VOD label (Wadleigh, Ho, Montaz, & Richardson, 2003).

Animal studies suggest that sinusoidal injury begins with rounding of the SECs that allows red cell embolization into the space of Disse (DeLeve et al., 2002; Wingard et al., 2004). Narrowing of the sinusoids results in decreased blood flow with subsequent hepatic congestion. Cellular debris created from the sloughing of SECs, red cell embolization, and injured hepatocytes leads to venular occlusion (Kumar, DeLeve, Kamath, & Tefferi, 2003) (see Figure 5). This process results in fibrin deposition, platelet aggregation, and possible thrombus formation seen in many (but not all) cases (see Figures 6 and 7). Approximately 14 days after myeloablative chemotherapy, deposits of extracellular matrix begin to fill the sinusoids. A marked increase in hepatic stellate cells along with the deposition of collagen eventually obliterates the sinusoids (DeLeve et al., 2002). A summary of this sinusoidal damage is found in Figure 8.

Although the differences in nomenclature (HSOS or VOD) are relevant in terms of mechanism of damage and medical treatment strategies, symptoms, risk factors, mortality, and supportive nursing care, needs are identical regardless of which name is used.

Defining Criteria

The diagnosis of HSOS is based on the Seattle (or modified Seattle) criteria or the Baltimore criteria and are compared in Table 1 (Bearman, 1995; Jones et al., 1987; McDonald et al., 1984). The Seattle criteria tend to be broader, whereas, generally, the Baltimore criteria capture more severe cases.

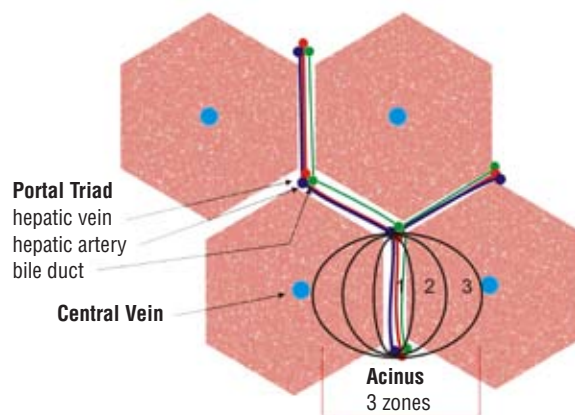


Figure 2. Portal Triad

Note. Image courtesy of Seth Eisenberg. Used with permission.

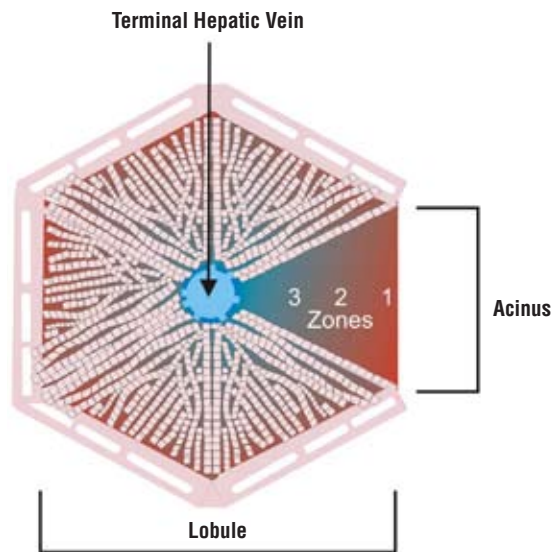


Figure 3. Lobule and Acinus

Note. Image courtesy of Seth Eisenberg. Used with permission.

The use of differing criteria by various research and clinical groups contributes to the difficulty in determining incidence and evaluating treatment efficacy, because a patient meeting one set of criteria might not be given the diagnosis when the other set of criteria are used. In general, HSOS (or VOD) occurs during the time frame beginning immediately after chemoradiotherapy and up to 30 days after transplant, although later instances have been reported (Coppell, Brown, & Perry, 2003).

Sinusoidal Injury

Several mechanisms for sinusoidal damage have been identified; however, because of the complex nature of the syndrome, they are likely the result of a multifactorial chain of events.

Direct Injury From Cytotoxic Metabolites

Sinusoidal endothelial cells, particularly those in zone three of the acini, are susceptible to injury from the metabolites of chemotherapy. Depletion of glutathione, a naturally occurring antioxidant and chemoprotectant produced by hepatocytes, is implicated in causing HSOS (Brown et al., 1998; DeLeve, 1996; Ibrahim et al., 2004; McDonald et al., 2003).

Cyclophosphamide commonly is used in myeloablative conditioning regimens for bone marrow and stem cell transplant. Two cyclophosphamide metabolites, carboxyethylphosphoramidate mustard (CEPM) and acrolein, are believed to play a major role in initiating the cascade of events leading to HSOS (Bearman, 2000; Kumar et al., 2003). Although total body irradiation (TBI) used in doses of 12–15 Gy does not cause HSOS, synergistic toxicity exists when TBI is given after cyclophosphamide (McDonald et al., 2003).

Oral busulfan also is used in conditioning regimens, frequently in conjunction with cyclophosphamide. Variations in serum concentrations commonly occur after the administration of busulfan, and a correlation between high serum levels and hepatic injury has been documented (Hassan et al., 2002; Russell et al., 2002). Busulfan traditionally has been ad-

ministered prior to cyclophosphamide because the highly emetogenic effects of the latter make it difficult to complete four days of oral chemotherapy. Studies have shown that busulfan, when dosed appropriately by monitoring pharmacokinetic levels, has little hepatotoxicity by itself (DeLeve et al., 2002; Kumar et al., 2003). However, even with careful dosing based on area under the curve, busulfan is believed to deplete glutathione stores, thus rendering the SECs more vulnerable to damage from the toxic cyclophosphamide metabolites (de Jonge, Huitema, Beijnen, & Rodenhuis, 2006; Kumar et al.). An IV formulation of busulfan has been available in the United States for several years. Some researchers have reported lower rates of HSOS with IV busulfan when compared to oral administration (Fisher, Barnes, & Nuss, 2006; Kashyap et al., 2002), although a recently published study did not support this finding (Cho et al., 2007). Compared to the oral route, IV busulfan has more predictable kinetics and may be given once daily instead of every six hours. Regardless of route, high-dose busulfan requires prophylaxis with phenytoin to prevent seizures. In busulfan-cyclophosphamide regimens, phenytoin increases the area under the curve of CEPM, therefore increasing cyclophosphamide toxicity. Furthermore, the relationship between hepatic toxicity and busulfan seems to be influenced by disease status (Cho et al.; McCune et al., 2007).

HSOS has been observed in autologous transplant recipients treated with a combination of busulfan, melphalan, and thiotepa. The incidence of HSOS with this regimen was reported by one site to be half that of cyclophosphamide-based regimens and tended to occur one to two weeks later in the transplant course (Lee, Gooley, Bensinger, Schiffman, & McDonald, 1999).

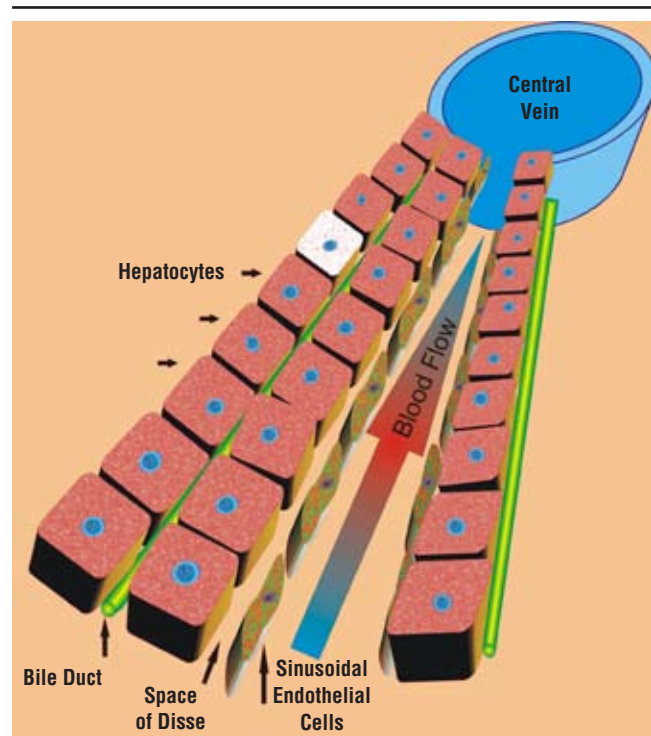


Figure 4. Normal Sinusoid

Note. Image courtesy of Seth Eisenberg. Used with permission.

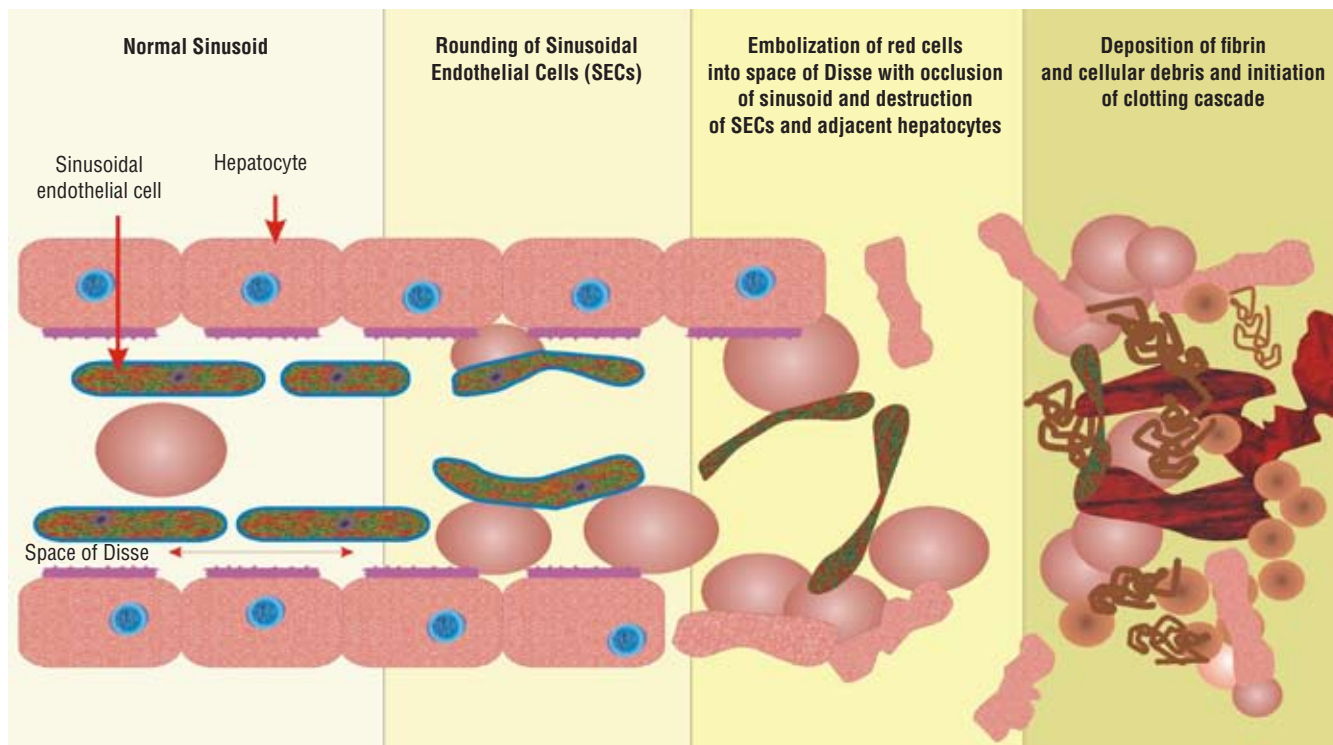


Figure 5. Sinusoidal Damage

Note. Image courtesy of Seth Eisenberg. Used with permission.

Cytokines

Cytokines have been implicated in contributing to SEC damage. Interleukin-6 (IL-6), IL-8, and tumor necrosis factor alpha (TNF α) are toxic to SECs. TNF α and IL1 β are released from endothelial cells and monocytes in the presence of cytotoxic drug metabolites and have procoagulant properties that initiate the clotting cascade and contribute to subsequent venular damage. Cytokine release results in platelet activation, further adding to the hypercoagulability often observed in HSOS (Coppell et al., 2003; Gharib, Bulley, Doyle, & Wynn, 2006; Kumar et al., 2003; Wadleigh, Ho, et al., 2003). Levels of transforming growth factor β and endothelin-1 also are elevated immediately prior to the development of HSOS, although their exact role is not understood fully (DeLeve et al., 2002; Kumar et al.). Vascular endothelial growth factor (VEGF) mediates numerous physiologic functions, most notably angiogenesis. VEGF is thought to be a marker for HSOS, and a positive correlation between increased levels and the development of HSOS has been observed (Iguchi et al., 2001).

Plasminogen activation inhibitor-1 (PAI-1), which is synthesized by endothelial cells, is stimulated by TNF α and IL1 β . PAI-1 blocks fibrinolysis, and increased levels serve as a specific marker for HSOS (Coppell et al., 2003; Gharib et al., 2006; Sartori et al., 2005; Smith et al., 2006).

Matrix Metalloproteinases

Matrix metalloproteinases (MMP) are a group of enzymes capable of degrading cellular components. DeLeve et al. (2003) studied MMP-2 and MMP-9 and noted markedly increased levels in rats that had been given monocrotaline, a chemical known to reliably cause HSOS in animal models. When an MMP

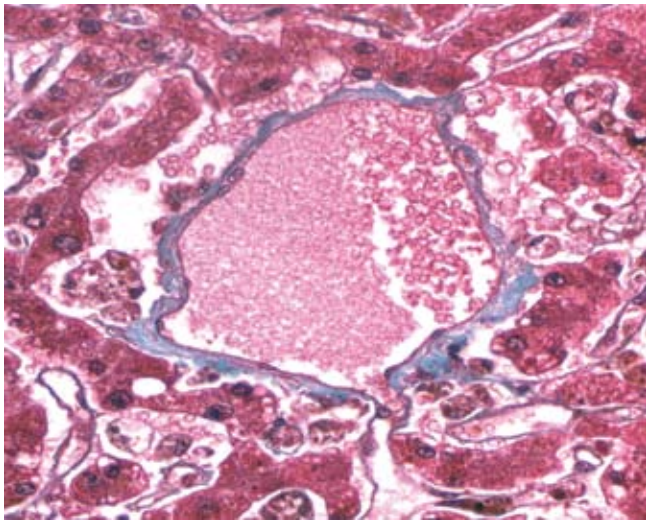
inhibitor was administered to rats along with monocrotaline, HSOS was prevented completely. No human studies have been published on MMP inhibitors in transplant recipients, although they are being examined for their potential antitumor effects (Hoekstra, Eskens, & Verweij, 2001).

Other factors implicated in the development of HSOS include decreased levels of protein C, antithrombin III (ATIII), hepatic nitric oxide, and the presence of lipopolysaccharides (DeLeve et al., 2003; Gharib et al., 2006; Iguchi et al., 2001). However, whether these are responsible for the chain of events or are a result of them is difficult to determine.

Diagnosis

Differentiating HSOS from other hepatic complications such as graft-versus-host disease (GVHD) or infection is important (Carreras, 2000) (see Table 2). No specific diagnostic studies or tests exist to diagnose HSOS accurately. Transjugular tissue biopsy, although safer than the percutaneous approach, poses a risk because HSOS usually occurs during a period of significant neutropenia, thrombocytopenia, and clotting abnormalities associated with the syndrome itself (Lin, Tierney, & Stadtmauer, 1993; Tay, Tinmouth, Fergusson, Huebsch, & Allan, 2007). Ultrasound and computed tomography can demonstrate the presence of hepatic abnormalities but do not provide specific diagnostic differentiation in early HSOS and therefore have limited value (Coppell et al., 2003).

Laboratory tests are useful, but most are not specific for HSOS. Elevation in serum bilirubin is the major abnormal laboratory value (Bearman, 1995) and higher levels are associated with greater mortality (Gooley, Rajvanshi, Schoch,



Note. Normal hepatic venule has a thin collagenized wall demonstrated by the trichrome stain. The sinusoids drain into the venule through small pores in the venous wall. Lumen is filled with red blood cells and plasma.

Figure 6. Normal Hepatic Venule

Note. Image courtesy of H.M. Shulman. Used with permission.

& McDonald, 2005; Litzow et al., 2002). Unfortunately, elevated bilirubin levels are not specific to HSOS and may be caused by other factors such as total parenteral nutrition toxicity, GVHD, cyclosporine toxicity, or infection (Bearman, 1995; Helmy, 2006).

The hepatic enzymes alanine aminotransferase (ALT) and aspartate aminotransferase (AST) are sensitive markers for hepatic injury and commonly are elevated in HSOS. Both also are seen in many other conditions. Although elevations in PAI-1 levels have been shown to be specific for HSOS, elevations can occur with sepsis (Nurnberger, Michelmann, Burdach, & Gobel, 1998), and not all laboratories are able to perform this test. Protein C and ATIII levels usually are decreased but have not proven to be accurate diagnostic indicators (DeLeve et al., 2002).

Risk Factors

Conditioning Regimen

High-dose chemotherapy using cyclophosphamide with or without busulfan is a well-documented risk factor (Helmy, 2006). Wide interpatient variability in cyclophosphamide metabolism may explain why some patients proceed to develop HSOS and others do not (McDonald et al., 2003). Busulfan followed by cyclophosphamide also seems to have an effect on risk (McCune et al., 2007). Other chemotherapeutic agents have been implicated as risk factors and are listed in Figure 9. Although not used as a pretransplant preparative regimen, the anti-CD33 monoclonal antibody gemtuzumab ozogamicin has been shown to cause HSOS (Rajvanshi, Shulman, Sievers, & McDonald, 2002) and is a significant risk factor for patients proceeding to transplant (Wadleigh, Richardson, et al., 2003). Regimens containing TBI may increase risk (Carreras, 2000), although the incidence is lower than those with busulfan-cyclophosphamide regimens (Hartman, Williams, & Dillon, 1998). ABO incompatible platelet transfu-

sions have been shown to be a risk factor in one study (Lapierre et al., 2005). A mechanism of action was not thoroughly described and the study has not been replicated.

Individual patient variables have an influence on risk. Glutathione is essential in the metabolism of many chemotherapeutic agents used in HSCT. Gene mutation, particularly polymorphisms of the glutathione S-transferase gene, can affect glutathione levels and lead to increased SEC toxicity (Coppell et al., 2003; Srivastava et al., 2004). Research in this area may prove beneficial in prescreening patients who are at higher risk for developing HSOS.

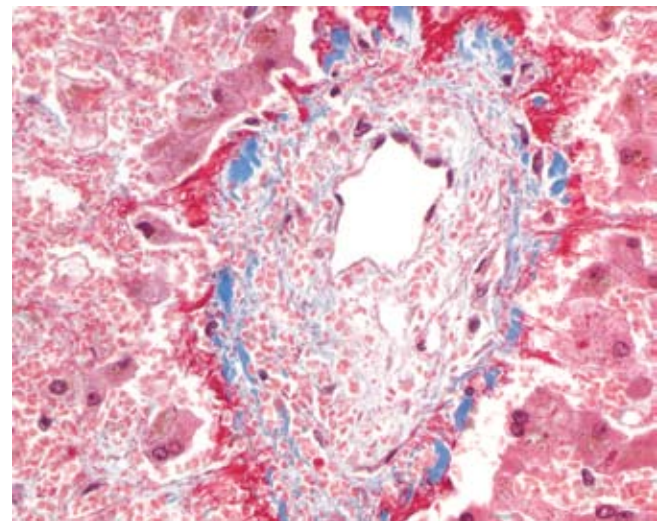
Acute GVHD may be a contributing factor because incidence of HSOS is lower in patients receiving syngeneic (twin) or T-cell depleted transplants when compared to mismatched and unrelated donors (Kumar et al., 2003). A direct causal effect may be difficult to establish because different conditioning regimens may be used.

Incidence

Until recently, the incidence of HSOS has varied from 0%–70% (Helmy, 2006). This large disparity is the result of differing diagnostic criteria; the lack of readily available, highly specific tests; and heterogeneous patient populations receiving a variety of conditioning regimens. For the past 10 years, the incidence has decreased to approximately 30% or less. Proposed explanations are summarized in Figure 10 (Wingard et al., 2004).

Prognosis

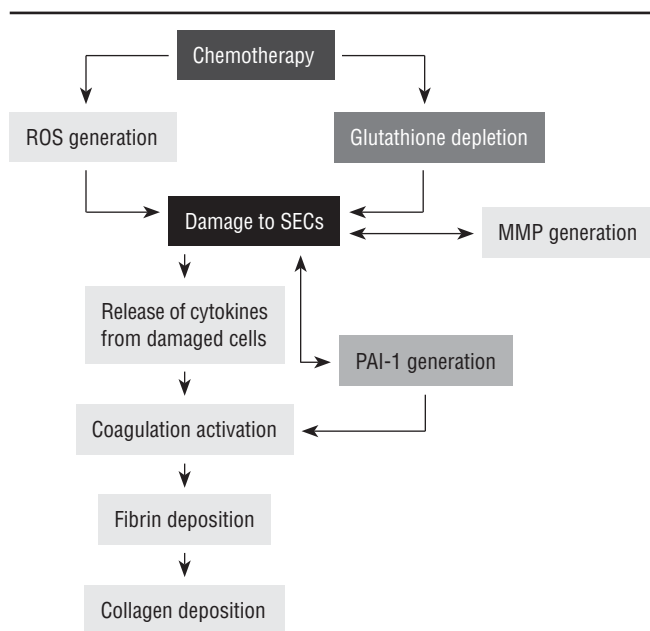
Survival can be predicted by plotting the rate of total bilirubin increase and weight gain during the first two weeks after transplant (Bearman et al., 1993). A substantial



Note. The venular lumen is 80% occluded by a widened subendothelial collection of embolized red cells and with extracellular matrix. Much of the surrounding hepatocytes have undergone hemorrhagic ischemic necrosis because of increased sinusoidal pressure and resistance to outflow.

Figure 7. Hepatic Venule in Patient With Hepatic Sinusoidal Obstruction Syndrome

Note. Image courtesy of H.M. Shulman. Used with permission.



MMP—matrix metalloproteinases; PAI-1—plasminogen activator inhibitor; ROS—reactive oxygen species; SECs—sinusoidal endothelial cells

Figure 8. Sinusoidal Damage Summary

Note. Figure courtesy of Seth Eisenberg. Used with permission.

increase in mortality is associated with elevations of more than 4 mg/dL serum bilirubin (Gooley et al., 2005). HSOS can be divided into three prognostic groups (McDonald et al., 1993). Mild HSOS resolves completely without specific interventions. Moderate HSOS requires careful supportive management and resolves in most patients. Severe HSOS does not resolve by 100 days after transplant or death. Historically, 90%–100% of patients with severe HSOS die, usually from renal failure, cardiopulmonary collapse, or gastrointestinal hemorrhage (Bearman et al., 1993; DeLeve et al., 2002; Helmy, 2006). A comparison of prognostic groups can be found in Figure 11.

Prevention and Treatment

Heparin

Based on the theory that HSOS was caused by hypercoagulability, researchers used low-dose IV unfractionated heparin (UFH) or subcutaneous low molecular weight heparin (LMWH) alone or in combination with other drugs for prevention and treatment (Pegram & Kennedy, 2001). Imran et al. (2006) performed a comprehensive review of published studies using prophylactic heparin. Twelve were identified, for a combined total of 2,782 patients. Two randomized studies, one using UFH and one using LMWH, showed benefit but lacked sufficient power to be statistically significant for preventing severe HSOS (Attal et al., 1992; Or et al., 1996). The remaining 10 cohort studies showed no benefit or lacked power to demonstrate efficacy (Batsis et al., 2006; Carreras et al., 1998; Hagglund et al., 1998; Horn, Reiss, Matthay, McMillan, & Cowan, 2002; Marsa-Vila et al., 1991; Reiss, Cowan, McMillan, & Horn, 2002; Rosenthal et al., 1996; Simon et al., 2001). Based on these findings, the researchers concluded that a combined analysis was not meaningful and that

definitive support of efficacy could not be made without future randomized, higher-powered studies.

A more recent nonrandomized study reported the results of prophylactic heparin on 85 pediatric patients. Fifty were given UFH; some also received lipoprostaglandin E₁ (PGE₁). Busulfan (either IV or oral) with cyclophosphamide was used in 61 patients. HSOS developed in 29% of patients. Twenty percent of those were classified as severe and all of them died. No difference was noted in the incidence of HSOS between patients receiving the oral or IV formulations of busulfan (Song, Seo, Moon, Ghim, & Im, 2006).

Despite these conflicting findings, clinicians may decide that prophylaxis with LMWH is appealing. All studies have shown the drug is well tolerated; however, the inconsistent results lend credence to the theory that hypercoagulability is not the primary cause in development of the disease and that other therapies are warranted (DeLeve et al., 2002).

Tissue Plasminogen Activator and Heparin

Recombinant tissue plasminogen activator (tPA) and continuous infusion UFH have been studied for treatment of severe HSOS. One study reported a response rate of 28%, but 88% had bleeding complications. Six of the 42 patients subsequently died from hemorrhage (Bearman, Lee, Baron, & McDonald, 1997). Another study reported reversal of symptoms in 29%, with significant bleeding in 35% (Schriber et al., 1999). Pulmonary hemorrhage was the most common site. Researchers concluded that timing of therapy initiation could play a role in treatment efficacy. Litzow et al. (2002) reported using tPA and UFH in 10 patients with severe HSOS. Nine out of 10 died. Bajwa et al. (2003) treated 12 children with tPA and a lower dose of UFH, and eight responded. Bleeding events were minimal, which most likely reflects the lower dose of heparin when compared with prior studies (5 u/kg per hour versus 150 u/kg per hour).

Ursodiol (Ursodeoxycholic Acid)

Ursodiol, an animal bile salt, is thought to work by making endogenous bile acids more hydrophilic, thus decreasing

Table 1. Defining Criteria for Hepatic Sinusoidal Obstructive Syndrome

Criteria	Definition
Seattle	At least two of the following within 30 days after transplant <ul style="list-style-type: none"> • Hepatomegaly and right upper quadrant pain • Jaundice • Unexplained weight gain or ascites
Modified Seattle	At least two of the following within 20 days after transplant <ul style="list-style-type: none"> • Hepatomegaly and right upper quadrant pain • Unexplained weight gain of more than 2% or ascites
Baltimore	Bilirubin greater than or equal to 2 within 21 days after transplant and at least two of the following <ul style="list-style-type: none"> • Painful hepatomegaly • Ascites • Weight gain of more than 5% of baseline

Note. Based on information from Bearman, 1995; Coppell et al., 2003; Gharib et al., 2006; Helmy, 2006; Imran et al., 2006; Kashyap et al., 2002; Kornblum et al., 2006; Tay et al., 2007.

Table 2. Differential Diagnosis

Symptom	Also Seen With
Rapid weight gain	Congestive heart failure Renal failure Sepsis syndrome Capillary leak syndrome
Hepatomegaly	Congestive heart failure Fungal infection Epstein-Barr virus lymphoproliferative disease Tumor involvement
Jaundice	Biliary infection Acute graft-versus-host disease Cyclosporine Cholestasis Drug or total parenteral nutrition injury Hemolysis

Note. Based on information from Carreras, 2000; McDonald et al., 1993.

proinflammatory cytokine production. A recently published review of clinical trials using ursodiol for prevention examined six studies and included a total of 824 patients (Tay et al., 2007). Four studies were randomized clinical trials and one was double-blind. The authors concluded that ursodiol successfully reduced the incidence of HSOS. Although encouraging, one of the reviewed studies reported a 4% rate of HSOS in the control group, reflecting a conspicuous absence of cyclophosphamide from the conditioning regimens (Ruutu et al., 2002). Busulfan was only used in 17 of 242 patients. Therefore, the apparent benefit of ursodiol is difficult to interpret for patients at moderate or high risk for HSOS. Another study compared ursodiol plus UFH to UFH alone in 165 patients. The incidence of HSOS was not statistically different between the two groups (Park et al., 2002). Ursodiol is only available orally, which may make compliance difficult when patients have mucositis and nausea; however, it is extremely well tolerated and may be beneficial in decreasing hepatic GVHD (McDonald, 2006).

Antithrombin III and Prostaglandin E₁

Levels of ATIII, a naturally occurring anticoagulant, decrease in patients developing HSOS (Haire et al., 1995). Several studies have used ATIII alone or in combination with other medications for prophylaxis but results have been mixed (Haire et al., 1998; Ibrahim et al., 2004; Patton et al., 1996). PGE₁ has a vasodilatory effect, can inhibit platelet function, and can provoke thrombolysis (Bearman, 1995; Wadleigh, Ho, et al., 2003). One study demonstrated a reduction in HSOS when PGE₁ was used compared to patients receiving UFH (Gluckman et al., 1990); however, a subsequent study by Bearman (1995) showed no benefit and demonstrated significant toxicity.

N-Acetylcysteine and Glutamine

N-acetylcysteine (NAC) is a thiol antioxidant that is thought to block the action of protein kinases and aid in glutathione synthesis (Ringden et al., 2000; Weiss et al., 2007). It has been used in Great Britain for treating paracetamol (acetaminophen) overdose and for preventing renal failure from contrast media (Weiss et al.). A case study of three patients with confirmed

HSOS, who had failed tPA, demonstrated complete resolution after NAC infusions (Ringden et al.). One small cohort study of patients at high risk who were receiving busulfan and cyclophosphamide reported no incidence of HSOS when NAC was given prophylactically, although the protocol was not specifically designed to demonstrate efficacy (Sjoo et al., 2003).

The nonessential amino acid glutamine plays a key role in the regulation of the tripeptide glutathione. As an antioxidant, glutathione protects the sinusoids from reactive oxygen species (Hong, Rounds, Helton, Robinson, & Wilmore, 1992). Zone three of the acini has relatively low quantities of glutathione and is particularly vulnerable to chemotherapy metabolites and subsequent damage (Brown et al., 1998). Glutamine supplementation had a protective effect against hepatotoxicity in one double-blinded study, but because of the small sample size and various conditioning regimens used, the results are difficult to interpret (Brown et al.). A case study of two patients demonstrated complete resolution of HSOS after infusions of glutamine and vitamin E (Goringe et al., 1998). Neither patient had severe HSOS, and whether their symptoms would have resolved on their own is not known.

Charcoal Hemofiltration

Charcoal hemofiltration, first used in rat models during the 1980s, has been shown to remove bilirubin by adsorption. Two patients with biopsy-proven HSOS were treated successfully using this procedure (Tefferi et al., 2001); one had failed ursodiol and defibrotide treatment and the other also had diffuse alveolar hemorrhage. Filtration may remove endothelial toxins and activated coagulation factors. No studies have been conducted to support these initial findings, and what role charcoal hemofiltration can play as supportive therapy is unclear.

Defibrotide

The most promising agent for prevention and treatment of HSOS is the investigational drug defibrotide. Defibrotide is single-stranded polydeoxyribonucleotide derived from porcine mucosa (Corbacioglu et al., 2004). It possesses anti-inflammatory and antithrombotic properties and increases fibrinolysis without significant anticoagulant effects (Bailey et al., 2002;

- Conditioning regimens containing cyclophosphamide
- Busulfan followed by cyclophosphamide
- Abdominal radiation
- Preexisting hepatic disease (hepatitis, bacterial, or fungal infections)
- Prior stem cell or bone marrow transplant
- Older age
- Advanced disease at time of transplant
- Poor performance status prior to transplant (e.g., Karnofsky Scale score < 90)
- Female gender
- Prior treatment with gemtuzumab
- Prior use of norethisterone
- Unrelated donor
- Major human lymphocyte antigen mismatch
- Elevated transaminase levels

Figure 9. Risk Factors for Developing Hepatic Sinusoidal Obstruction Syndrome

Note. Based on information from Carreras, 2000; Cesaro, 2005; de Jonge et al., 2006; Hassan et al., 2002; Helmy, 2006; McCune, 2007; Reiss et al., 2002.

- Increased use of nonmyeloablative transplant containing fludarabine (Hogan et al., 2004)
- Use of stem cells in place of marrow (Dey et al., 2007; Fisher et al., 1998)
- Increased use of pharmacokinetic dosing for busulfan (Lee et al., 2005)
- Treating patients sooner after diagnosis (DeLeve et al., 2002)
- Fewer patients with hepatitis C (DeLeve et al., 2002)
- Fewer dose-escalation studies (DeLeve et al., 2002)
- Generally healthier patient population (Kalayoglu-Besisik et al., 2005)

Figure 10. Reasons for Declining Incidence

Kalayoglu-Besisik et al., 2005). When administered via IV, defibrotide binds to the sinusoidal endothelium and up-regulates the release of endogenous tPA, PGE₂, prostacyclin, and thrombomodulin (DeLeve et al., 2002; Helmy, 2006; Richardson et al., 1998).

Two small studies have examined the use of defibrotide for prophylaxis. None of the patients in either study developed HSOS, although the patients were heterogeneous in their diagnoses, risk factors, and conditioning regimens (Chalandon et al., 2004; Dignan et al., 2007). Initial studies using defibrotide for treatment of severe HSOS reported complete resolution in 36% of patients (Richardson et al., 2002). In another study, complete resolution was observed in 50% of patients, although a variety of prophylactic therapies (heparin, ursodiol, ATIII, L-glutamine, and ursodiol) had been used (Corbacioglu et al., 2004). Side effects of defibrotide are minor and include nausea, abdominal cramps, and mild hypotension (Kornblum et al., 2006). Although the use of defibrotide for severe HSOS has produced a marked improvement in survival from the less than or equal to 10% historical rates, additional therapies clearly still are needed.

Possible Complications and Associated Nursing Care

Few resources exist for the nursing care of patients with HSOS. The two most comprehensive articles were published in the 1980s (Ford, McClain, & Cunningham, 1983; Grandt, 1989), and a recent article describing the critical care implications of patients with HSCT briefly touched on the topic (Saria & Gosselin-Acomb, 2007). Despite the scarcity of research, nursing assessments, plans, and interventions can be directed toward management of each affected organ system because HSOS frequently results in multisystem organ failure (Haussmann et al., 2006). Figure 12 summarizes nursing interventions for HSOS.

Renal Complications

HSOS is the primary cause of renal failure within the first three weeks after transplant (Soubani, 2006). Often resembling hepatorenal syndrome (HRS), HSOS primarily is a result of vasoconstriction or inadequate glomerular perfusion (Han & Hyzy, 2006; Zager, 1994). Albumin, which is produced by hepatocytes, exerts a strong oncotic pull by drawing fluids from the extracellular domain back into the vascular compartment (Peck & Griffith, 1988; Siconolfi, 1995). Hepatic dysfunction with resultant hypoalbuminemia leads to ascites and peripheral edema (Bixby, 2006; Metheny, 2000). Renal function worsens as the kidneys attempt to correct for a hypovolemic state. Portal hypertension and venous outflow obstruction also contribute to ascites. Patients often complain of feeling full or bloated, and bowel sounds will be hypoactive or absent (Winkelman, 2004).

A ratio of 30:1 for blood urea nitrogen (BUN) to creatinine is common and typifies a “prerenal” condition (Tasota & Tate, 2000; Zager, 1994). A normal ratio is 20:1. This differs significantly from acute tubular necrosis in etiology and presentation, although eventually it can lead to tubular damage (Gines, Guevara, Arroyo, & Rodes, 2003; Wujcik, Ballard, & Camp-Sorrell, 1994). Hyponatremia is common and patients initially will present with normal or slightly decreased urine output. Urine will be dark yellow to brown in color with a specific gravity of more than 1.025 (Mudge & Carlson, 1992). Uremia causes weakness, fatigue, pruritus and can interfere with hemostasis (Chikotas, Gunderman, & Oman, 2006; Stark, 1994). If hepatic function continues to deteriorate, renal function worsens accordingly and often requires hemodialysis.

Nursing management includes twice daily weights, daily abdominal girth measurement, and orthostatic blood pressures (Ezzone & Schmit-Pokorny, 2007; Ford et al., 1983; Keller, 2001; Wujcik et al., 1994). Abdominal girth should be measured across the same location on the patient’s abdomen. A permanent marker may be useful for this purpose. Because one of the goals of management is to minimize fluid retention, increasing weight or girth is associated with worsening HSOS and should be reported to the physician.

Orthostatic vital signs assist in determining intravascular volume status (Bradley & Davis, 2003; Roper, 1996). The patient must be able to tolerate lying flat, which may be difficult in the presence of large ascites or respiratory compromise. IV fluids should be restricted, although this poses a challenge because patients are hypovolemic. Repletion of volume with packed red blood cells has been used, but its effectiveness is not well supported (Keller, 2001; Wujcik et al., 1994). Without correcting the underlying hepatic dysfunction, albumin infusions may worsen the third space effects as a result of its oncotic pull. The overall benefit of blood transfusions remains controversial (Metheny, 2000). Gentle diuresis with spironolactone has been used in an effort to mobilize fluid (Ford et al., 1983; Grandt, 1989). Spironolactone has relatively few side effects and increases sodium and water excretion while sparing potassium. Unfortunately it only is available orally. Loop diuretics should be avoided because they will deplete vascular volume, further worsening the “prerenal” state (Ford et al.). Low-dose dopamine (1–2 mcg/kg per hour) has been used in an attempt to increase renal perfusion but has not been proven effective and can cause numerous side effects (Bellomo, Chapman, Finfer, Hickling, & Myburgh, 2000; Keller; Marik, 2002; Zager, 1994).

Accurate intake and output records are imperative. Nurses need to be aware of the volumes of IV medications and the

Mild

- Self-limiting
- Resolves completely without specific interventions

Moderate

- Requires diuretics or opiates for pain management
- Resolves in most patients

Severe

- Does not resolve within 100 days after transplant or death

Figure 11. Prognosis for Degrees of Hepatic Sinusoidal Obstruction Syndrome

Note. Based on information from Bearman, 1995; McDonald et al., 1993.

Renal

- Perform daily weights and report changes.
- Measure abdominal girth and report increased measurements.
- Monitor blood urea nitrogen and creatinine and report increased values.
- Keep strict intake and output records and report imbalances in context of weight, girth, and other organ function.
- Obtain postural vital signs and report changes.
- Anticipate fluid restriction (IV and oral), and monitor closely.
- Coordinate with pharmacy to mix medications in minimal volume.
- Anticipate orders for spironolactone.
- Avoid concomitant infusion of nephrotoxic medications.
- Monitor cyclosporine and tacrolimus levels.

Cardiovascular

- Assess for orthostatic hypotension and report findings.
- Auscultate heart sounds for friction rub, pericardial effusion, or tamponade.
- Anticipate orders for inotropic medications to support blood pressure.

Respiratory

- Elevate head of bed or encourage patient to sit in chair.
- Auscultate lungs for adventitious breath sounds.
- Assess oxygen saturation or arterial blood gas as needed.
- Anticipate orders for oxygen.
- Assist with paracentesis.

Hematologic

- Monitor daily complete blood count and coagulation panel.
- Assess all sites for bleeding.
- Administer blood product support (platelets, packed red blood cells, fresh frozen plasma).

Integument

- Maintain skin integrity.
- Avoid use of soap.
- Use moisturizers for dry skin.
- Elevate feet.
- Anticipate orders for topical or oral antipruritic medication.
- Instruct patient to rub gently instead of scratching.
- Use distraction (e.g., video games, music) to help patient cope with pruritus.

Neurologic

- Assess for edema, pigmentation changes, and pruritus.
- Assess for changes in mental status.
- Maintain safe environment.
- Anticipate order for lactulose.
- Use opiates and sedating medications cautiously.

Psychosocial

- Provide patient and family with rationale for increased assessments, physiologic changes, and need for increased assistance with self-care.
- Allow patients and family time to adjust to changes in physical appearance, and provide opportunities to express concerns, fears, and emotions.
- Encourage use of multidisciplinary support team, including pastoral care and social work.
- Be prepared to discuss end-of-life issues.

Figure 12. Nursing Interventions for Hepatic Sinusoidal Obstruction Syndrome

Note. Based on information from Bellomo et al., 2000; Berg, 1990; Bradley & Davis, 2003; Ezzone & Schmidt-Pokorny, 2007; Ford et al., 1983; Grandt, 1989; Keller, 2001; Marik, 2002; Metheny, 2000; Mudge & Carlson, 1992; Pegram & Kennedy, 2001; Roper, 1996; Stark, 1994; Wujcik et al., 1994; Zager, 1994.

rate of infusions. Open communication with the pharmacy is crucial in ensuring medications are mixed in minimal volume without compromising stability. Concomitant administration of nephrotoxic medications (e.g., cyclosporine with amphotericin or an aminoglycoside) should be avoided whenever possible (Ford et al., 1983; Mudge & Carlson, 1992). Cyclosporine and

tacrolimus levels should be monitored because these medications can worsen renal failure (Pegram & Kennedy, 2001).

Cardiovascular Complications

Cardiovascular complications are tied closely to renal function. Patients may be hypotensive or exhibit orthostatic hypotension related to intravascular depletion. Assess patient for fall risk and institute precautions accordingly. Uremia can irritate the pericardium, causing pericardial effusions with or without tamponade (Berg, 1990; Ford et al., 1983; Stark, 1994). Patients may complain of midsternal chest pain from a friction rub, which should be differentiated from esophagitis. The heart should be auscultated during inspiration and expiration while the patient is in a high Fowler's position. Tamponade may be identified by the presence of a pulsus paradoxus. Hemodynamic instability often requires aggressive treatment with inotropic agents to maintain blood pressure.

Respiratory Complications

Respiratory compromise is caused by fluid overload, capillary leak, or aspiration pneumonia secondary to decreased mentation (Pierson, 2006; Soubani, 2006; Winkelman, 2004). Abdominal distention can contribute to hypoventilation by exerting pressure on the diaphragm. The reduced tidal volume results in tachypnea as the body attempts to compensate. Paracentesis may be indicated for improving ventilatory status and relieving pain (Bearman, 1995; Wadleigh, Ho, et al., 2003). Auscultate lungs for the presence of rales. Although oxygen saturations are useful in assessing hypoxia, they will not indicate carbon dioxide retention or pH abnormalities, in which case arterial blood gases will be necessary. Elevate the head of bed to facilitate optimal lung expansion. Many patients will require supplemental oxygen and, if deterioration continues, mechanical ventilation. Once ventilatory support is required, the prognosis is grim. Patients requiring intubation, who also have respiratory and either renal or hepatic failure, carry a mortality rate approaching 100% (Rubinfeld & Crawford, 1996).

Hematologic Complications

HSOS usually occurs during a period of thrombocytopenia. Elevations in BUN and serum bilirubin interfere with the normal coagulation pathways, further increasing the likelihood of bleeding (Chikotas et al., 2006; Grandt, 1989; Johnson & Quiet). Spontaneous bleeding from the nares, oral mucosa, and gastrointestinal tract can occur. In addition to platelets and packed red blood cells, fresh frozen plasma or fibrinogen may be needed to replace clotting factors (Ford et al., 1983; Wujcik et al., 1994). Bleeding potential also may be increased in patients receiving prophylactic UFH (Johnson & Quiet, 2004). Managing fluids and medications along with an increase in blood product support can pose a challenge, even with multiple-lumen catheters, because oliguric or anuric patients cannot tolerate large quantities of fluids.

Integumentary Complications

Ascites and edema increase the risk of injury and skin breakdown. Maintaining skin integrity becomes paramount. Discuss with the patient and family the importance of keeping feet elevated whenever possible. Protective footwear should be encouraged to decrease the likelihood of trauma from stepping on or colliding with hard objects when ambu-

lating (e.g., IV pole wheels). Meticulous skin care is needed. Skin should be patted dry and not rubbed (McConn, 1987).

Urea and bilirubin cause pruritis (Bosonnet, 2003; Chikotas et al., 2006; Winkelman, 2004). Scratching should be discouraged because of increased risk of bleeding and infection. Antihistamines such as diphenhydramine or hydroxyzine are not usually effective. Chlorpheniramine, clemastine, or cyproheptadine may be useful, particularly at night because of their sedative effects. Newer antihistamines such as loratadine, fexofenadine, or cetirizine may be effective but have not been studied in this population (Rhiner & Slatkin, 2006). The 5-HT₃ receptor antagonist ondansetron has been successfully used for pruritis in non-HSOS hepatic failure and may be beneficial (Bosonnet). Naloxone hydrochloride also has been used to treat hepatic-induced pruritis, although its usefulness in this setting may be limited by concomitant parenteral opiate analgesia (Bosonnet; Rhiner & Slatkin).

Soap should be avoided because of its drying effects. Cool temperatures lower the itch threshold (Bosonnet, 2003). Lotions are useful in preventing dry skin, particularly in edematous areas. Loose cotton clothing is preferred over synthetics or wool because it allows better air exchange and decreases sweating that can potentiate itching (McConn, 1987). Talcum powder should be avoided, although cornstarch can be useful in reducing friction in skin fold areas, provided the skin is intact (McConn). Plain calamine lotion and topical steroids usually are not beneficial. However, crotamiton 10% may reduce itching. Relief has been reported with Sarna® (Stiefel Laboratories, Inc.) lotion, which promotes a sensation of cooling. Colloidal oatmeal baths also may provide soothing relief (McConn).

Neurologic Complications

Mental status changes can be a result of renal or hepatic failure. Uremic encephalopathy is caused by deterioration in the glomerular filtration rate. Lethargy is common, although mentation may improve after hemodialysis. Hepatic encephalopathy (HE) can range from mild to severe, and has been associated with elevations in serum ammonia levels (Han & Hyzy, 2006; Saria & Gosselin-Acomb, 2007). Ammonia is created by the breakdown of nitrogenous waste products in the intestine. Normally it is detoxified by the liver into urea

and excreted by the kidneys. Although ammonia has been implicated as the primary source of HE, venous and arterial levels do not always correlate with the degree of encephalopathy observed, and new research suggests multifactorial causes (Faint, 2006; Shawcross & Jalan, 2005). Lactulose, a nonabsorbable disaccharide, continues to be the mainstay of treatment in reducing ammonia levels despite weak evidence supporting its efficacy (Faint). Medication clearance often is impaired with hepatic dysfunction, resulting in half-life prolongation. Patients requiring IV opiates or anxiolytics, such as lorazepam, should be monitored for confusion, sedation, or respiratory depression. Patients with mental status changes also are at high risk for aspiration pneumonia, particularly in light of coexisting mucositis and should, therefore, be assisted in performing daily oral hygiene and with oral intake.

Psychosocial Problems

Alterations in body image occur from ascites, edema, and changes in skin pigmentation. Severe edema can interfere with normal ADL. Skin color can range from yellow to dark tan depending on the patient's natural pigmentation and bilirubin level. Because profound changes in body appearance often coincide with a decline in overall clinical status, families and patients will need multidisciplinary support, including nursing care, pastoral care, and social work services to assist with these physical changes in addition to possible end-of-life issues.

Summary

HSOS is a multifaceted, potentially life-threatening complication of myeloablative therapy. It has profound physiologic and psychosocial implications for patients who have undergone the rigors of hematopoietic stem cell transplant. Nursing care is extremely complex and challenging and requires a thorough understanding of pathophysiology and symptom management.

Author Contact: Seth Eisenberg, RN, OCN®, can be reached at seisenbe@seattlecca.org, with copy to editor at ONFEditor@ons.org.

References

- Attal, M., Hugué, F., Rubie, H., Huynh, A., Charlet, J.P., Payen, J.L., et al. (1992). Prevention of hepatic veno-occlusive disease after bone marrow transplantation by continuous infusion of low-dose heparin: A prospective, randomized trial. *Blood*, *79*(11), 2834–2840.
- Bairey, O., Kirgner, I., Yakobi, M., Hamdan, A., Ben-Ari, Z., & Shaklai, M. (2002). Clinical severe hepatic veno-occlusive disease during induction treatment of acute monoblastic leukemia managed with defibrotide. *American Journal of Hematology*, *69*(4), 281–284.
- Bajwa, R.P., Cant, A.J., Abinun, M., Flood, T.J., Hodges, S., Hale, J.P., et al. (2003). Recombinant tissue plasminogen activator for treatment of hepatic veno-occlusive disease following bone marrow transplantation in children: Effectiveness and a scoring system for initiating treatment. *Bone Marrow Transplantation*, *31*(7), 591–597.
- Batsis, I., Yannaki, E., Kaloyannidis, P., Sakellari, I., Smias, C., Georgoulis, I., et al. (2006). Venous-occlusive disease prophylaxis with fresh frozen plasma and heparin in bone marrow transplantation. *Thrombosis Research*, *118*(5), 611–618.
- Bearman, S.I. (1995). The syndrome of hepatic veno-occlusive disease after marrow transplantation. *Blood*, *85*(11), 3005–3020.
- Bearman, S.I. (2000). Venous-occlusive disease of the liver. *Current Opinion in Oncology*, *12*(2), 103–109.
- Bearman, S.I., Anderson, G.L., Mori, M., Hinds, M.S., Shulman, H.M., & McDonald, G.B. (1993). Venous-occlusive disease of the liver: Development of a model for predicting fatal outcome after marrow transplantation. *Journal of Clinical Oncology*, *11*(9), 1729–1736.
- Bearman, S.I., Lee, J.L., Baron, A.E., & McDonald, G.B. (1997). Treatment of hepatic veno-occlusive disease with recombinant human tissue plasminogen activator and heparin in 42 marrow transplant patients. *Blood*, *89*(5), 1501–1506.
- Bellomo, R., Chapman, M., Finfer, S., Hickling, K., & Myburgh, J. (2000). Low-dose dopamine in patients with early renal dysfunction: A placebo-controlled randomised trial. Australian and New Zealand Intensive Care Society (ANZICS) Clinical Trials Group. *Lancet*, *356*(9248), 2139–2143.

- Berg, J. (1990). Assessing for pericarditis in the end-stage renal disease patient. *Dimensions of Critical Care Nursing*, 9(5), 266–271.
- Bixby, M. (2006). Third-spacing: Where has all the fluid gone? Nursing made incredibly easy! 42–53. Retrieved July 12, 2007, from OVID.
- Bosonnet, L. (2003). Pruritis: Scratching the surface. *European Journal of Cancer Care*, 12(2), 162–165.
- Bradley, J.G., & Davis, K.A. (2003). Orthostatic hypotension. *American Family Physician*, 68(12), 2393–2398.
- Bras, G., Berry, D.M., & Gyorgy, P. (1957). Plants as aetiological factor in veno-occlusive disease of the liver. *Lancet*, 272(6976), 960–962.
- Brown, S.A., Goringe, A., Fegan, C., Davies, S.V., Giddings, J., Whittaker, J.A., et al. (1998). Parenteral glutamine protects hepatic function during bone marrow transplantation. *Bone Marrow Transplant*, 22(3), 281–284.
- Carreras, E. (2000). Veno-occlusive disease of the liver after hemopoietic cell transplantation. *European Journal of Haematology*, 64(5), 281–291.
- Carreras, E., Bertz, H., Arcese, W., Vernant, J.P., Tomas, J.F., Hagglund, H., et al. (1998). Incidence and outcome of hepatic veno-occlusive disease after blood or marrow transplantation: A prospective cohort study of the European Group for Blood and Marrow Transplantation. European Group for Blood and Marrow Transplantation Chronic Leukemia Working Party. *Blood*, 92(10), 3599–3604.
- Cesaro, S., Pillon, M., Talenti, E., Toffolutti, T., Calore, E., Tridello, G., et al. (2005). A prospective survey on incidence, risk factors and therapy of hepatic veno-occlusive disease in children after hematopoietic stem cell transplantation. *Haematologica*, 90(10), 1396–1404.
- Chalandon, Y., Roosnek, E., Mermillod, B., Newton, A., Ozsahin, H., Wacker, P., et al. (2004). Prevention of veno-occlusive disease with defibrotide after allogeneic stem cell transplantation. *Biology of Blood and Marrow Transplantation*, 10(5), 347–354.
- Chikotas, N., Gunderman, A., & Oman, T. (2006). Uremic syndrome and end-stage renal disease: Physical manifestations and beyond. *Journal of the American Academy of Nurse Practitioners*, 18(5), 195–202.
- Cho, Y.H., Lim, H.A., Lee, M.H., Kim, I., Lee, J.S., Park, S., et al. (2007). Pharmacokinetics and tolerability of intravenous busulfan in hematopoietic stem cell transplantation. *Clinical Transplantation*, 21(3), 417–422.
- Coppell, J.A., Brown, S.A., & Perry, D.J. (2003). Veno-occlusive disease: Cytokines, genetics, and haemostasis. *Blood Reviews*, 17(3), 63–70.
- Corbacioglu, S., Greil, J., Peters, C., Wulfraat, N., Laws, H.J., Dilloo, D., et al. (2004). Defibrotide in the treatment of children with veno-occlusive disease (VOD): A retrospective multicentre study demonstrates therapeutic efficacy upon early intervention. *Bone Marrow Transplant*, 33(2), 189–195.
- de Jonge, M.E., Huitema, A.D., Beijnen, J.H., & Rodenhuis, S. (2006). High exposures to bioactivated cyclophosphamide are related to the occurrence of veno-occlusive disease of the liver following high-dose chemotherapy. *British Journal of Cancer*, 94(9), 1226–1230.
- DeLeve, L.D. (1996). Cellular target of cyclophosphamide toxicity in the murine liver: Role of glutathione and site of metabolic activation. *Hepatology*, 24(4), 830–837.
- DeLeve, L.D., Shulman, H.M., & McDonald, G.B. (2002). Toxic injury to hepatic sinusoids: Sinusoidal obstruction syndrome (veno-occlusive disease). *Seminars in Liver Disease*, 22(1), 27–42.
- DeLeve, L.D., Wang, X., Kanel, G.C., Ito, Y., Bethea, N.W., McCuskey, M.K., et al. (2003). Decreased hepatic nitric oxide production contributes to the development of rat sinusoidal obstruction syndrome. *Hepatology*, 38(4), 900–908.
- Dey, B. R., Shaffer, J., Yee, A. J., McAfee, S., Caron, M., Power, K., et al. (2007). Comparison of outcomes after transplantation of peripheral blood stem cells versus bone marrow following an identical nonmyeloablative conditioning regimen. *Bone Marrow Transplant*, 40(1), 19–27.
- Dignan, F., Gujral, D., Ethell, M., Evans, S., Treleaven, J., Morgan, G., et al. (2007). Prophylactic defibrotide in allogeneic stem cell transplantation: Minimal morbidity and zero mortality from veno-occlusive disease. *Bone Marrow Transplantation*, 40(1), 79–82.
- Ezzone, S., & Schmit-Pokorny, K. (2007). *Blood and marrow stem cell transplantation: Principles, practice, and nursing insights*. Sudbury, MA: Jones and Bartlett.
- Faint, V. (2006). The pathophysiology of hepatic encephalopathy. *Nursing in Critical Care*, 11(2), 69–74.
- Fisher, D.C., Vredenburg, J.J., Petros, W.P., Hussein, A., Berry, D.A., Elkordy, M., et al. (1998). Reduced mortality following bone marrow transplantation for breast cancer with the addition of peripheral blood progenitor cells is due to a marked reduction in veno-occlusive disease of the liver. *Bone Marrow Transplant*, 21(2), 117–122.
- Fisher, V., Barnes, Y.J., & Nuss, S.L. (2006). Pretransplant conditioning in adults and children: Dose assurance with intravenous busulfan [Online Exclusive]. *Oncology Nursing Forum*, 33(2), E36–E43. Retrieved April 3, 2008, from <http://ons.metapress.com/content/r1176553g3731060/?p=f6dbb586e61d4709a3454a45f80d621d&pi=23>
- Ford, R., McClain, K., & Cunningham, B.A. (1983). Veno-occlusive disease following marrow transplantation. *Nursing Clinics of North America*, 18(3), 563–568.
- Gharib, M.I., Bulley, S.R., Doyle, J.J., & Wynn, R.F. (2006). Venous occlusive disease in children. *Thrombosis Research*, 118(1), 27–38.
- Gines, P., Guevara, M., Arroyo, V., & Rodes, J. (2003). Hepatorenal syndrome. *Lancet*, 362(9398), 1819–1827.
- Gluckman, E., Jolivet, I., Scrobhaci, M.L., Devergie, A., Traineau, R., Bourdeau-Esperou, H., et al. (1990). Use of prostaglandin E1 for prevention of liver veno-occlusive disease in leukaemic patients treated by allogeneic bone marrow transplantation. *British Journal of Haematology*, 74(3), 277–281.
- Gooley, T.A., Rajvanshi, P., Schoch, H.G., & McDonald, G.B. (2005). Serum bilirubin levels and mortality after myeloablative allogeneic hematopoietic cell transplantation. *Hepatology*, 41(2), 345–352.
- Goringe, A.P., Brown, S., O'Callaghan, U., Rees, J., Jebb, S., Elia, M., et al. (1998). Glutamine and vitamin E in the treatment of hepatic veno-occlusive disease following high-dose chemotherapy. *Bone Marrow Transplant*, 21(8), 829–832.
- Grandt, N.C. (1989). Hepatic veno-occlusive disease following bone marrow transplantation. *Oncology Nursing Forum*, 16(6), 813–817.
- Hagglund, H., Remberger, M., Klaesson, S., Lonnqvist, B., Ljungman, P., & Ringden, O. (1998). Norethisterone treatment, a major risk factor for veno-occlusive disease in the liver after allogeneic bone marrow transplantation. *Blood*, 92(12), 4568–4572.
- Haire, W.D., Ruby, E.L., Gordon, B.G., Patil, K.D., Stephens, L.C., Kotulak, G.D., et al. (1995). Multiple organ dysfunction syndrome in bone marrow transplantation. *JAMA*, 274(16), 1289–1295.
- Haire, W.D., Ruby, E.L., Stephens, L.C., Reed, E., Tarantolo, S.R., Pavletic, Z.S., et al. (1998). A prospective randomized double-blind trial of anti-thrombin III concentrate in the treatment of multiple-organ dysfunction syndrome during hematopoietic stem cell transplantation. *Biology of Blood and Marrow Transplantation*, 4(3), 142–150.
- Han, M.K., & Hyzy, R. (2006). Advances in critical care management of hepatic failure and insufficiency. *Critical Care Medicine*, 34(9 Suppl.), S225–S231.
- Hartman, A.R., Williams, S.F., & Dillon, J.J. (1998). Survival, disease-free survival and adverse effects of conditioning for allogeneic bone marrow transplantation with busulfan/cyclophosphamide versus total body irradiation: A meta-analysis. *Bone Marrow Transplantation*, 22(5), 439–443.
- Hassan, Z., Hellstrom-Lindberg, E., Alsadi, S., Edgren, M., Hagglund, H., & Hassan, M. (2002). The effect of modulation of glutathione cellular content on busulfan-induced cytotoxicity on hematopoietic cells in vitro and in vivo. *Bone Marrow Transplantation*, 30(3), 141–147.
- Hausmann, U., Fischer, J., Eber, S., Scherer, F., Seger, R., & Gungor, T. (2006). Hepatic veno-occlusive disease in pediatric stem cell transplantation: Impact of pre-emptive antithrombin III replacement and combined antithrombin III/defibrotide therapy. *Haematologica*, 91(6), 795–800.
- Helmy, A. (2006). Review article: Updates in the pathogenesis and therapy of hepatic sinusoidal obstruction syndrome. *Alimentary Pharmacology and Therapeutics*, 23(1), 11–25.
- Hoekstra, R., Eskens, F.A., & Verweij, J. (2001). Matrix metalloproteinase inhibitors: Current developments and future perspectives. *The Oncologist*, 6(5), 415–427.
- Hogan, W. J., Maris, M., Storer, B., Sandmaier, B. M., Maloney, D. G.,

- Schoch, H. G., et al. (2004). Hepatic injury after nonmyeloablative conditioning followed by allogeneic hematopoietic cell transplantation: a study of 193 patients. *Blood*, *103*(1), 78–84.
- Hong, R.W., Rounds, J.D., Helton, W.S., Robinson, M.K., & Wilmore, D.W. (1992). Glutamine preserves liver glutathione after lethal hepatic injury. *Annals of Surgery*, *215*(2), 114–119.
- Horn, B., Reiss, U., Matthay, K., McMillan, A., & Cowan, M. (2002). Venooclusive disease of the liver in children with solid tumors undergoing autologous hematopoietic progenitor cell transplantation: A high incidence in patients with neuroblastoma. *Bone Marrow Transplant*, *29*(5), 409–415.
- Ibrahim, R.B., Peres, E., Dansey, R., Abidi, M.H., Abella, E.M., & Klein, J. (2004). Antithrombin III in the management of hematopoietic stem-cell transplantation-associated toxicity. *Annals of Pharmacotherapy*, *38*(6), 1053–1059.
- Iguchi, A., Kobayashi, R., Yoshida, M., Kobayashi, K., Matsuo, K., Kitajima, I., et al. (2001). Vascular endothelial growth factor (VEGF) is one of the cytokines causative and predictive of hepatic veno-occlusive disease (VOD) in stem cell transplantation. *Bone Marrow Transplantation*, *27*(11), 1173–1180.
- Imran, H., Tleyjeh, I.M., Zirakzadeh, A., Rodriguez, V., & Khan, S.P. (2006). Use of prophylactic anticoagulation and the risk of hepatic veno-occlusive disease in patients undergoing hematopoietic stem cell transplantation: A systematic review and meta-analysis. *Bone Marrow Transplantation*, *37*(7), 677–686.
- Jakubik, L.D., Cockerham, J., Altmann, A.R., & Grossman, M.B. (2003). The ABCs of pediatric laboratory interpretation: Understanding the CBC with differential and LFTs. *Pediatric Nursing*, *29*(2), 97–103.
- Johnson, G., & Quiett, K. (2004). Hematologic effects. In S. Ezzone (Ed.), *Hematopoietic stem cell transplantation: A manual for nursing practice* (pp. 133–145). Pittsburgh, PA: Oncology Nursing Society.
- Jones, R.J., Lee, K.S., Beschoner, W.E., Vogel, V.G., Grochow, L.B., Braine, H.G., et al. (1987). Venooclusive disease of the liver following bone marrow transplantation. *Transplantation*, *44*(6), 778–783.
- Kalayoglu-Besisik, S., Yenerel, M.N., Caliskan, Y., Ozturk, S., Besisik, F., & Sargin, D. (2005). Time-related changes in the incidence, severity, and clinical outcomes of hepatic veno-occlusive disease in hematopoietic stem cell transplantation patients during the past 10 years. *Transplant Proceedings*, *37*(5), 2285–2289.
- Kashyap, A., Wingard, J., Cagnoni, P., Roy, J., Tarantolo, S., Hu, W., et al. (2002). Intravenous versus oral busulfan as part of a busulfan/cyclophosphamide preparative regimen for allogeneic hematopoietic stem cell transplantation: Decreased incidence of hepatic venoocclusive disease (HVOD), HVOD-related mortality, and overall 100-day mortality. *Biology of Blood and Marrow Transplantation*, *8*(9), 493–500.
- Keller, C. (2001). Bone marrow and stem cell transplantation. In S. Otto (Ed.), *Oncology nursing* (4th ed., pp. 731–759). Philadelphia, PA: Mosby.
- Kornblum, N., Ayyanar, K., Benimetskaya, L., Richardson, P., Iacobelli, M., & Stein, C.A. (2006). Defibrotide, a polydisperse mixture of single-stranded phosphodiester oligonucleotides with life-saving activity in severe hepatic veno-occlusive disease: Clinical outcomes and potential mechanisms of action. *Oligonucleotides*, *16*(1), 105–114.
- Kumar, S., DeLeve, L.D., Kamath, P.S., & Tefferi, A. (2003). Hepatic veno-occlusive disease (sinusoidal obstruction syndrome) after hematopoietic stem cell transplantation. *Mayo Clinic Proceedings*, *78*(5), 589–598.
- Lapierre, V., Mahe, C., Auperin, A., Stambouli, F., Oubouzar, N., Tramalloni, D., et al. (2005). Platelet transfusion containing ABO-incompatible plasma and hepatic veno-occlusive disease after hematopoietic transplantation in young children. *Transplantation*, *80*(3), 314–319.
- Lee, J., Choi, S., Lee, J., Kim, S., Park, C., Chi, H., et al. (2005). Decreased incidence of hepatic veno-occlusive disease and fewer hemostatic derangements associated with intravenous busulfan vs oral busulfan in adults conditioned with busulfan + cyclophosphamide for allogeneic bone marrow transplantation. *Annals of Hematology*, *84*(5), 321–330.
- Lee, J.L., Gooley, T., Bensinger, W., Schiffman, K., & McDonald, G.B. (1999). Venooclusive disease of the liver after busulfan, melphalan, and thiotepa conditioning therapy: Incidence, risk factors, and outcome. *Biology of Blood and Marrow Transplantation*, *5*(5), 306–315.
- Lin, E.M., Tierney, D.K., & Stadtmauer, E.A. (1993). Autologous bone marrow transplantation. A review of the principles and complications. *Cancer Nursing*, *16*(3), 204–213.
- Litzow, M.R., Repoussis, P.D., Schroeder, G., Schembri-Wismayer, D., Batts, K.P., Anderson, P.M., et al. (2002). Venooclusive disease of the liver after blood and marrow transplantation: Analysis of pre- and post-transplant risk factors associated with severity and results of therapy with tissue plasminogen activator. *Leukemia and Lymphoma*, *43*(11), 2099–2107.
- Marik, P.E. (2002). Low-dose dopamine: A systematic review. *Intensive Care Medicine*, *28*(7), 877–883.
- Marsa-Vila, L., Gorin, N.C., Laporte, J.P., Labopin, M., Dupuy-Montbrun, M.C., Fouillard, L., et al. (1991). Prophylactic heparin does not prevent liver veno-occlusive disease following autologous bone marrow transplantation. *European Journal of Haematology*, *47*(5), 346–354.
- McCann, R. (1987). Skin changes following bone marrow transplantation. *Cancer Nursing*, *10*(2), 82–84.
- McCune, J.S., Batchelder, A., Deeg, H.J., Gooley, T., Cole, S., Phillips, B., et al. (2007). Cyclophosphamide following targeted oral busulfan as conditioning for hematopoietic cell transplantation: Pharmacokinetics, liver toxicity, and mortality. *Biology of Blood and Marrow Transplantation*, *13*(7), 853–862.
- McDonald, G.B. (2006). Advances in prevention and treatment of hepatic disorders following hematopoietic cell transplantation. *Best Practice and Research Clinical Haematology*, *19*(2), 341–352.
- McDonald, G.B., Hinds, M.S., Fisher, L.D., Schoch, H.G., Wolford, J.L., Banaji, M., et al. (1993). Venooclusive disease of the liver and multiorgan failure after bone marrow transplantation: A cohort study of 355 patients. *Annals of Internal Medicine*, *118*(4), 255–267.
- McDonald, G.B., Sharma, P., Matthews, D.E., Shulman, H.M., & Thomas, E.D. (1984). Venooclusive disease of the liver after bone marrow transplantation: Diagnosis, incidence, and predisposing factors. *Hepatology*, *4*(1), 116–122.
- McDonald, G.B., Slattery, J.T., Bouvier, M.E., Ren, S., Batchelder, A.L., Kalthorn, T.F., et al. (2003). Cyclophosphamide metabolism, liver toxicity, and mortality following hematopoietic stem cell transplantation. *Blood*, *101*(5), 2043–2048.
- Metheny, N. (2000). Fluid and electrolyte balance: Nursing considerations (4th ed., pp. 353–363). Philadelphia, PA: Lippincott Williams & Wilkins.
- Mudge, C., & Carlson, L. (1992). Hepatorenal syndrome. *AACN Clinical Issues in Critical Care Nursing*, *3*(3), 614–632.
- Nurnberger, W., Michelmann, I., Burdach, S., & Gobel, U. (1998). Endothelial dysfunction after bone marrow transplantation: Increase of soluble thrombomodulin and PAI-1 in patients with multiple transplant-related complications. *Annals of Hematology*, *76*(2), 61–65.
- Or, R., Nagler, A., Shpilberg, O., Elad, S., Naparstek, E., Kapelushnik, J., et al. (1996). Low molecular weight heparin for the prevention of venooclusive disease of the liver in bone marrow transplantation patients. *Transplantation*, *61*(7), 1067–1071.
- Park, S.H., Lee, M.H., Lee, H., Kim, H.S., Kim, W. S., et al. (2002). A randomized trial of heparin plus ursodiol vs. heparin alone to prevent hepatic veno-occlusive disease after hematopoietic stem cell transplantation. *Bone Marrow Transplantation*, *29*(2), 137–143.
- Patton, D.F., Harper, J.L., Wooldridge, T.N., Gordon, B.G., Coccia, P., & Haire, W.D. (1996). Treatment of venooclusive disease of the liver with bolus tissue plasminogen activator and continuous infusion antithrombin III concentrate. *Bone Marrow Transplantation*, *17*(3), 443–447.
- Peck, S.N., & Griffith, D.J. (1988). Reducing portal hypertension and variceal bleeding. *Dimensions of Critical Care Nursing*, *7*(5), 269–279.
- Pegram, A.A., & Kennedy, L.D. (2001). Prevention and treatment of venooclusive disease. *Annals of Pharmacotherapy*, *35*(7–8), 935–942.
- Pierson, D.J. (2006). Respiratory considerations in the patient with renal failure. *Respiratory Care*, *51*(4), 413–422.
- Rajvanshi, P., Shulman, H.M., Sievers, E.L., & McDonald, G.B. (2002). Hepatic sinusoidal obstruction after gemtuzumab ozogamicin (Mylotarg) therapy. *Blood*, *99*(7), 2310–2314.
- Reiss, U., Cowan, M., McMillan, A., & Horn, B. (2002). Hepatic venooclusive

- disease in blood and bone marrow transplantation in children and young adults: Incidence, risk factors, and outcome in a cohort of 241 patients. *Journal of Pediatric Hematology/Oncology*, 24(9), 746–750.
- Rhiner, M., & Slatkin, N. (2006). Pruritis, fever, and sweats. In B. Ferrell & N. Coyle (Eds.), *Textbook of palliative nursing* (2nd ed., pp. 345–363). Oxford: Oxford University Press.
- Richardson, P.G., Elias, A.D., Krishnan, A., Wheeler, C., Nath, R., Hoppensteadt, D., et al. (1998). Treatment of severe veno-occlusive disease with defibrotide: Compassionate use results in response without significant toxicity in a high-risk population. *Blood*, 92(3), 737–744.
- Richardson, P.G., Murakami, C., Jin, Z., Warren, D., Momtaz, P., Hoppensteadt, D., et al. (2002). Multi-institutional use of defibrotide in 88 patients after stem cell transplantation with severe veno-occlusive disease and multisystem organ failure: Response without significant toxicity in a high-risk population and factors predictive of outcome. *Blood*, 100(13), 4337–4343.
- Ringden, O., Remberger, M., Lehmann, S., Hentschke, P., Mattsson, J., Klaesson, S., et al. (2000). N-acetylcysteine for hepatic veno-occlusive disease after allogeneic stem cell transplantation. *Bone Marrow Transplant*, 25(9), 993–996.
- Roper, M. (1996). Back to basics assessing orthostatic vital signs. *American Journal of Nursing*, 96(8), 43–46.
- Rosenthal, J., Sender, L., Secola, R., Killen, R., Millerick, M., Murphy, L., et al. (1996). Phase II trial of heparin prophylaxis for veno-occlusive disease of the liver in children undergoing bone marrow transplantation. *Bone Marrow Transplantation*, 18(1), 185–191.
- Rubinfeld, G.D., & Crawford, S.W. (1996). Withdrawing life support from mechanically ventilated recipients of bone marrow transplants: A case for evidence-based guidelines. *Annals of Internal Medicine*, 125(8), 625–633.
- Russell, J.A., Tran, H.T., Quinlan, D., Chaudhry, A., Duggan, P., Brown, C., et al. (2002). Once-daily intravenous busulfan given with fludarabine as conditioning for allogeneic stem cell transplantation: Study of pharmacokinetics and early clinical outcomes. *Biology of Blood and Marrow Transplantation*, 8(9), 468–476.
- Ruutu, T., Eriksson, B., Remes, K., Juvonen, E., Volin, L., Remberger, M., et al. (2002). Ursodeoxycholic acid for the prevention of hepatic complications in allogeneic stem cell transplantation. *Blood*, 100(6), 1977–1983.
- Saria, M.G., & Gosselin-Acomb, T.K. (2007). Hematopoietic stem cell transplantation: Implications for critical care nurses. *Clinical Journal of Oncology Nursing*, 11(1), 53–63.
- Sartori, M.T., Spiezia, L., Cesaro, S., Messina, C., Paris, M., Pillon, M., et al. (2005). Role of fibrinolytic and clotting parameters in the diagnosis of liver veno-occlusive disease after hematopoietic stem cell transplantation in a pediatric population. *Thrombosis and Haemostasis*, 93(4), 682–689.
- Schriber, J., Milk, B., Shaw, D., Christiansen, N., Baer, M., Slack, J., et al. (1999). Tissue plasminogen activator (tPA) as therapy for hepatotoxicity following bone marrow transplantation. *Bone Marrow Transplantation*, 24(12), 1311–1314.
- Shawcross, D., & Jalan, R. (2005). Dispelling myths in the treatment of hepatic encephalopathy. *Lancet*, 365(9457), 431–433.
- Shulman, H.M., Fisher, L.B., Schoch, H.G., Henne, K.W., & McDonald, G.B. (1994). Veno-occlusive disease of the liver after marrow transplantation: Histological correlates of clinical signs and symptoms. *Hepatology*, 19(5), 1171–1181.
- Shulman, H.M., McDonald, G.B., Matthews, D., Doney, K.C., Kopecky, K.J., Gauvreau, J.M., et al. (1980). An analysis of hepatic veno-occlusive disease and centrilobular hepatic degeneration following bone marrow transplantation. *Gastroenterology*, 79(6), 1178–1191.
- Siconolfi, L.A. (1995). Clarifying the complexity of liver function tests. *Nursing*, 25(5), 39–44.
- Simon, M., Hahn, T., Ford, L.A., Anderson, B., Swinnich, D., Baer, M.R., et al. (2001). Retrospective multivariate analysis of hepatic veno-occlusive disease after blood or marrow transplantation: Possible beneficial use of low molecular weight heparin. *Bone Marrow Transplantation*, 27(6), 627–633.
- Sjoo, F., Aschan, J., Barkholt, L., Hassan, Z., Ringden, O., & Hassan, M. (2003). N-acetyl-L-cysteine does not affect the pharmacokinetics or myelosuppressive effect of busulfan during conditioning prior to allogeneic stem cell transplantation. *Bone Marrow Transplantation*, 32(4), 349–354.
- Smith, L.H., Dixon, J.D., Stringham, J.R., Eren, M., Elokda, H., Crandall, D.L., et al. (2006). Pivotal role of PAI-1 in a murine model of hepatic vein thrombosis. *Blood*, 107(1), 132–134.
- Song, J.S., Seo, J.J., Moon, H.N., Ghim, T., & Im, H.J. (2006). Prophylactic low-dose heparin or prostaglandin E1 may prevent severe veno-occlusive disease of the liver after allogeneic hematopoietic stem cell transplantation in Korean children. *Journal of Korean Medical Science*, 21(5), 897–903.
- Soubani, A.O. (2006). Critical care considerations of hematopoietic stem cell transplantation. *Critical Care Medicine*, 34(9 Suppl.), S251–S267.
- Srivastava, A., Poonkuzhali, B., Shaji, R.V., George, B., Mathews, V., Chandy, M., et al. (2004). Glutathione S-transferase M1 polymorphism: A risk factor for hepatic veno-occlusive disease in bone marrow transplantation. *Blood*, 104(5), 1574–1577.
- Stark, J.L. (1994). Interpreting BUN/creatinine levels: It's not as simple as you think. *Nursing*, 24(9), 58–61.
- Tasota, F.J., & Tate, J. (2000). Assessing renal function. *Nursing*, 30(5), 20.
- Tay, J., Tinmouth, A., Fergusson, D., Huebsch, L., & Allan, D.S. (2007). Systematic review of controlled clinical trials on the use of ursodeoxycholic acid for the prevention of hepatic veno-occlusive disease in hematopoietic stem cell transplantation. *Biology of Blood and Marrow Transplantation*, 13(2), 206–217.
- Tefferi, A., Kumar, S., Wolf, R.C., Lacy, M.Q., Inwards, D.J., Gloor, J.M., et al. (2001). Charcoal hemofiltration for hepatic veno-occlusive disease after hematopoietic stem cell transplantation. *Bone Marrow Transplantation*, 28(10), 997–999.
- Wadleigh, M., Ho, V., Momtaz, P., & Richardson, P. (2003). Hepatic veno-occlusive disease: Pathogenesis, diagnosis and treatment. *Current Opinion in Hematology*, 10(6), 451–462.
- Wadleigh, M., Richardson, P.G., Zahrieh, D., Lee, S.J., Cutler, C., Ho, V., et al. (2003). Prior gemtuzumab ozogamicin exposure significantly increases the risk of veno-occlusive disease in patients who undergo myeloablative allogeneic stem cell transplantation. *Blood*, 102(5), 1578–1582.
- Weiss, L., Reich, S., Zeira, M., Or, R., Resnick, I.B., Slavin, S., et al. (2007). N-acetylcysteine mildly inhibits the graft-versus-leukemia effect but not the lymphokine activated cells (LAK) activity. *Transplant Immunology*, 17(3), 198–202.
- Wingard, J.R., Nichols, W.G., & McDonald, G.B. (2004). Supportive care. *Hematology*, 372–389.
- Winkelman, L. (2004). Malignant ascites. In C. Yarbro, M. Frogge, & M. Goodman (Eds.), *Cancer symptom management* (pp. 401–412). Sudbury, MA: Jones and Bartlett.
- Wujcik, D., Ballard, B., & Camp-Sorrell, D. (1994). Selected complications of allogeneic bone marrow transplantation. *Seminars in Oncology Nursing*, 10(1), 28–41.
- Zager, R.A. (1994). Acute renal failure in the setting of bone marrow transplantation. *Kidney International*, 46(5), 1443–1458.

Free Continuing Nursing Education credit is available by completing an online test. To access the test for this and other articles, visit www.onsforum.org, select "CE from ONF," and choose the test(s) you would like to take. You will be prompted to enter your Oncology Nursing Society username and password.