

Inflammatory Breast Cancer

Case Study

M.A., a 44-year-old female, is nulliparous, premenopausal, and single and has no chronic health problems. Four weeks ago, she had a small tattoo placed on the superior aspect of her right breast. She reports awakening one night with a severe aching pain in her right breast, rating it as a 4 on the 0–10 pain scale. The pain does not radiate and is not affected by activity.

The next day, her right breast appears erythematous compared to the rest of her chest wall and is painful to touch. She decides to seek treatment from an urgent care facility where she is examined by an internist who finds her afebrile; all other vital signs are normal. Review of systems is noncontributory other than the breast complaint. Examination reveals that M.A. is in no acute distress, with no abnormal findings except for the right breast's moderate erythema, increased warmth to touch, and mild (1+) edema. No discrete masses are discovered on clinical breast examination. The tattoo site is not draining and appears to be well healed. The complete blood count is normal. The internist diagnoses M.A. with cellulitis secondary to placement of the tattoo. He prescribes oral amoxicillin/clavulanate potassium 500 mg twice daily for 10 days and oral ibuprofen 600 mg three times a day as needed for pain. He asks M.A. to follow up with her gynecologist or internist if the symptoms worsen or persist.

One week later, M.A.'s pain has not increased, yet her right breast is now significantly larger than the left, with increased erythema and warmth, and the nipple appears to be flattening. She also notes that the skin pores seem more open and pronounced, but she remains afebrile. She has been compliant with the oral antibiotic therapy and has taken an average of two doses of ibuprofen daily, one in the morning and one in the evening before bed. M.A. calls her gynecologist and is scheduled for an appointment for the following morning. The gynecologist is unable to palpate any discrete mass but is concerned about the overall appearance of M.A.'s right breast, which now has pitting 2+ edema and *peau d'orange* (i.e., skin that resembles an orange peel) on the lateral surface. She

changes the antibiotic to levofloxacin, continues ibuprofen for pain management, and schedules a bilateral diagnostic mammogram to be done the following day. The mammogram does not show any nodules or masses but reveals skin thickening on the lateral aspect of the right breast. The gynecologist refers M.A. to a comprehensive breast clinic at a nearby academic medical center, where she is examined by a breast surgeon, medical oncologist, and radiation therapist. An incisional biopsy of the skin is performed, but only inflammatory, not malignant, cells are found. The treatment team makes a presumptive diagnosis of inflammatory breast cancer based on the clinical presentation.

Clinical Problem Solving

Addressing this clinical challenge is Associate Editor Susan Moore, RN, MSN, ANP, AOCN®, an oncology nurse practitioner in the Division of Hematology and Oncology at Rush University Medical Center in Chicago, IL.

Given the symptoms reported by M.A., what are the possible differential diagnoses that might delay a diagnosis of inflammatory breast cancer?

M.A.'s case study is common among women with inflammatory breast cancer. Because no discrete breast mass exists and the presentation triad of pain, erythema, and edema is nonspecific, an infectious cause for the symptoms is usually the initial diagnosis and treatment is given accordingly. Only after the symptoms fail to respond to antibiotic therapy does further workup proceed, which can cause a delay of several weeks. The possible differential diagnoses for M.A.'s symptoms and presentation include mastitis, cellulitis, and inflammatory breast cancer.

Mastitis encompasses two distinct categories with respect to the timing of the onset: mastitis diagnosed during pregnancy or lactation and nonpuerperal mastitis. Mastitis can be chronic granulomatous or infectious. Regardless of the subtype, mastitis has several distinct characteristics on presentation: pain, swelling, and erythema in the affected breast. Women with mastitis may have a fever and complain of feeling ill. Leukocytosis also is

present (Johnson, 2003). Mastitis generally is unilateral and occurs with no tendency toward a particular quadrant of the breast.

Chronic granulomatous mastitis is a rare benign breast condition characterized by necrotizing granulomas and abscess, occurring primarily in women of childbearing age. Most women are diagnosed within five years of their last childbirth, but pregnant and lactating women are not immune to this disorder. Mammogram often reveals a radiographically visible mass. Chronic granulomatous mastitis mimics breast cancer in terms of physical and radiographic findings; however, definitive diagnosis can be confirmed only by histopathology (Azlina, Ariza, Arni, & Hisham, 2003). In a study of women with this diagnosis, breast-feeding, smoking, or hormonal treatment did not appear to be associated with patients' diagnoses (Azlina et al.).

Nonpuerperal mastitis, also termed duct ectasia, breast abscess, or simple mastitis, has the clinical presentation of erythema, swelling, and painful infiltrate in the breast. Fever rarely is present. Most cases are of bacterial origin that may be evident on microbiologic examination of aspirate from the infiltrated area, which often is located in the major milk ducts behind the areola (Peters, Kiesslich, & Pahnke, 2002). Smoking is a risk factor for this form of mastitis. Most women present with an abscess that is easily detectable on sonographic examination.

Although benign mastitis is not considered a risk factor for invasive breast cancer, in a study of 277 patients with nonpuerperal mastitis, 5 women were independently identified as having breast cancer within 12 months following the benign mastitis diagnosis (Peters

The solutions offered to the clinical problems posed in this column are the opinions of the author and do not represent the opinions or recommendations of the Oncology Nursing Society, the Oncology Nursing Forum, or the editorial staff. (Mention of specific products and opinions related to those products do not indicate or imply endorsement by the Oncology Nursing Forum or the Oncology Nursing Society.)

Digital Object Identifier: 10.1188/05.ONF.907-911

et al., 2002). Large-scale studies have not been carried out to confirm this incidence, but women with benign mastitis warrant long-term surveillance after diagnosis.

Cellulitis has a presentation similar to mastitis, but a palpable or radiographically detectable mass is rarely present. The skin is erythematous, warm to the touch, and mildly edematous. The onset generally is sudden, and systemic symptoms such as fever and chills are seen in some patients (Brewer, Hahn, Rohrbach, Bell, & Baddour, 2000). Nonsurgical wounds to the breast, including body piercing, tattooing, or animal bites, can result in infection of the skin, or cellulitis. Most often evaluated by emergency physicians or internists, apparent cellulitis should be followed carefully to rule out inflammatory breast cancer as the true diagnosis (Givens & Luszczak, 2002). Cellulitis is treated with antibiotic therapy and pain management. If conservative treatment does not change the clinical presentation in three to four weeks, inflammatory breast cancer should be presumed to be the cause until or unless it is definitively ruled out.

Women with breast cancer treated with breast conservation surgery (i.e., lumpectomy) are at risk for delayed breast cellulitis. In an early retrospective chart analysis, Staren et al. (1996) described delayed breast cellulitis as a condition that presented a significant diagnostic and management dilemma, affecting about 5% of women who undergo breast conservation therapy. A retrospective analysis showed that 3.4% of women were diagnosed with delayed breast cellulitis following lumpectomy (Zippel et al., 2003). The increased use of lumpectomy for primary breast cancer has resulted in an increased incidence of this condition (Zippel et al.). Delayed breast cellulitis can be distinguished from immediate postoperative infection by the delayed onset (weeks or months after surgery) and lack of fever, but the condition can be difficult to differentiate from inflammatory breast cancer. Many cases of delayed breast cellulitis occur well after completion of adjuvant chemotherapy or radiation therapy, with the typical occurrence more than three months after lumpectomy and within the first six months after completion of radiation therapy (Staren et al.). Clinical presentation includes erythema, edema, *peau d'orange*, and occasionally warmth at the site. This condition usually occurs on the dependent portion of the breast around and below the nipple areola. Interestingly, delayed breast cellulitis-associated erythema typically is more visible when a patient is sitting or standing but fades when the patient is supine. No accompanying systemic symptoms such as fever exist (Zippel et al.). In their case control study, Brewer et al. (2000) found the following risk factors for development: hematoma drainage, postoperative ecchymosis, lymphedema, higher volume of resected breast tissue, number of prior breast biopsies, and number of breast seroma aspirations. No significant as-

sociation between delayed breast cellulitis and the number of mammograms, total radiation dose, or development of radiation dermatitis was found.

Inflammatory breast cancer, a rapidly progressing type of breast cancer, has a high mortality rate and is the most serious of the differential diagnoses for M.A. Almost all cases of inflammatory breast cancer are evaluated initially in the primary care setting (Johnson, 2003). The condition often is misdiagnosed as mastitis or cellulitis, resulting in weeks or months of antibiotic therapy and observation. As a result, many cases of inflammatory breast cancer already have metastasized at the time of diagnosis. The rapid onset of inflammatory breast cancer in a previously healthy breast is one of the most outstanding characteristics of the disease (Lerebours, Bieche, & Lidereau, 2005). At initial presentation, the clinical triad of erythema, edema, and pain is present in the breast tissue. The edema generally is quite remarkable, with a classic *peau d'orange* appearance to the affected breast (see Figure 1). Constitutional symptoms such as fever and asthenia typically are absent; in fact, many women have no prodromal signs but suddenly experience pain in the affected breast and only then note erythema and *peau d'orange*.

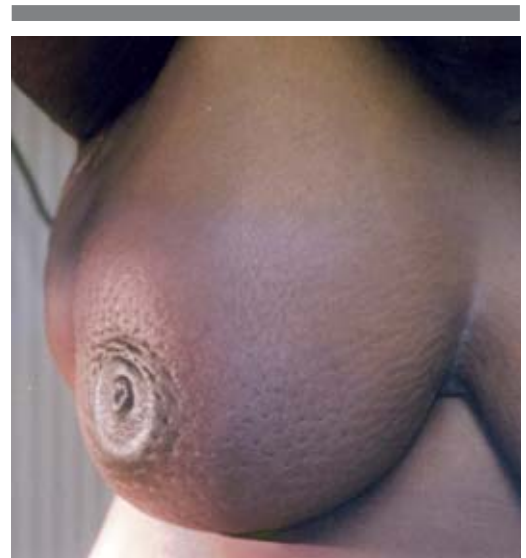What are the distinguishing characteristics of inflammatory breast cancer? Can any specific molecular markers assist the surgeon or pathologist in making a definitive diagnosis of this disease?

Inflammatory breast cancer is characterized by rapid onset of erythema, edema, and pain in the affected breast (Giordano & Hortobagyi, 2003); however, only half of patients typically have an associated palpable mass (Galmarini, Garbovesky, Galmarini, & Galmarini, 2002). The rapid onset can help to differentiate between inflammatory breast cancer and a neglected locally advanced breast cancer that has developed secondary inflammatory characteristics (Giordano & Hortobagyi). Increased skin thickness, asymmetric widening of the subcutaneous lymphatic vessels (the cause of *peau d'orange* skin changes), and increased tissue density in the affected breast commonly are seen. Leukocytosis is not present, and patients generally feel well. They may present for workup after minimal improvement following antibiotic therapy for presumed mastitis or cellulitis.

Diagnosis may be made on the basis of clinical presentation alone. Less than half of inflammatory breast cancer cases show a discrete mass on mammography, yet a bilateral diagnostic mammogram and ultrasound should be done nonetheless. Although a mass may not

be present, the mammogram may show skin thickening, trabecular thickening, and axillary adenopathy that are present in the majority of patients (Kushwaha, Whitman, Stelling, Cristofanilli, & Buzdar, 2000). Once a physical examination and mammogram have been completed, obtaining tissue for histologic confirmation is the standard of care. An incisional biopsy is preferred to fine needle aspiration so that sufficient tumor and skin samples with dermal lymphatics are retrieved to assist in the diagnosis (Jaiyesimi, Buzdar, & Hortobagyi, 1992; Lerebours et al., 2005).

Inflammatory breast cancer is not associated with a particular histologic subtype (Giordano & Hortobagyi, 2003); however, it has distinct biologic characteristics that differentiate it from noninflammatory breast cancer. These tumors typically are high grade, aneuploid, and hormone receptor negative (Charafe-Jauffret et al., 2004; Giordano & Hortobagyi). Mutations in the *p53* gene also are more likely to be present (Turpin et al., 2002). Overexpression of HER2/neu, epidermal growth factor receptors, and cathepsin D generally are present (Charafe-Jauffret et al.). Turpin et al. studied 161 patients with inflammatory breast cancer and found that HER2/neu overexpression was twice as frequent in inflammatory breast cancer as in noninflammatory tumors. In their retrospective chart analysis, Charafe-Jauffret et al. found that, along with three other variables (i.e., estrogen receptor negativity, MIB1 > 20, and mucin 1 cytoplasmic staining), HER2/neu



Note. This photo reveals the clinical characteristics of inflammatory breast cancer: erythema, edema, nipple flattening, and *peau d'orange*.

Figure 1. Typical Appearance of Inflammatory Breast Cancer

Note. Photo courtesy of Rush University Medical Center. Reprinted with permission.

and E-cadherin were significantly associated with inflammatory breast cancer. This analysis sought to identify an “inflammatory signature” or the protein expression specific for the inflammatory breast cancer phenotype. The probability that a breast cancer expressing this full phenotype at diagnosis was inflammatory breast cancer was 90.5%. Van Golen (2003) reported that overexpression of *RhoC GTPase* was highly correlated with an inflammatory carcinoma phenotype; 90% of inflammatory tumors compared with 38% of noninflammatory tumors overexpressed *RhoC GTPase*. In addition, *RhoC GTPase* appears to function as a transforming oncogene, conferring a highly invasive phenotype similar to that seen in inflammatory breast cancer. Lost in inflammatory breast cancer, a novel gene, was lost in 80% of inflammatory specimens in comparison with 21% of non-inflammatory tumors (van Golen, Wu, Qiao, Bao, & Merajver, 2000).

Is inflammatory breast cancer treated differently from other invasive breast cancers?

The current standard of care involves multimodality treatment, including surgery, chemotherapy, and radiation therapy. Following diagnosis, a full staging workup should be done to assess for distant metastases; however, inflammatory breast cancer should be considered a systemic disease at initial presentation even if the staging workup is negative (Ozmen et al., 2003). If the workup is negative, induction or neoadjuvant sequential chemotherapy, including an anthracycline-containing regimen followed by a taxane, generally paclitaxel, should be initiated immediately. This sequential regimen is associated with a higher probability of objective remission and should be used routinely as the standard of care (Cristofanilli, Buzdar, & Hortobagyi, 2003).

Women who are HER2/neu-positive should be given neoadjuvant trastuzumab (Herceptin®, Genentech, Inc., South San Francisco, CA) concomitantly with paclitaxel. An alternative neoadjuvant regimen including docetaxel and carboplatin with or without trastuzumab has been shown to be highly effective in treating women with locally advanced breast cancer (Chang et al., 2005). No data on long-term survival and safety are available at present; however, the survival gains associated with the use of trastuzumab in HER2-overexpressing metastatic breast cancer suggest that including trastuzumab in inflammatory breast cancer treatment may be beneficial (Montemurro & Aglietta, 2005). The optimal duration of trastuzumab therapy after surgery remains to be determined, but current recommendations suggest a total of 12 months (Tuma, 2005).

During the course of chemotherapy, patients should be assessed frequently for clinical response to therapy. As long as the condition does not progress, neoadjuvant

chemotherapy should continue (Galmarini et al., 2002). If progression occurs, a restaging workup should be done prior to changing chemotherapy agents (see Figure 2).

Following optimal response to neoadjuvant chemotherapy, a mastectomy and node dissection are performed. Breast-conserving therapy currently is not a standard approach (Shenkier et al., 2004). No consensus exists regarding the efficacy of mastectomy versus radiation therapy alone following chemotherapy in inflammatory breast cancer. Novel chemotherapy regimens may provide additional benefit combined with mastectomy. If the mastectomy specimen and axillary nodes are free of disease, patients can begin locoregional radiation therapy. If the tumor is hormone receptor positive,

adjuvant hormonal therapy with tamoxifen or an aromatase inhibitor may be used for premenopausal or postmenopausal women, respectively. A partial response to neoadjuvant chemotherapy is evidenced by the presence of a tumor in either the mastectomized breast or axillary nodes. In that case, four cycles of adjuvant chemotherapy, including antineoplastic drugs not used during neoadjuvant treatment, should be given. This adjuvant therapy is followed by radiation and hormonal therapy when the tumor is hormone receptor positive. Locoregional radiation therapy should be delivered to the chest wall and to the supraclavicular and axillary nodes (Shenkier et al.). A dose escalation irradiation study of 115 patients with nonmetastatic inflammatory breast cancer indicated that

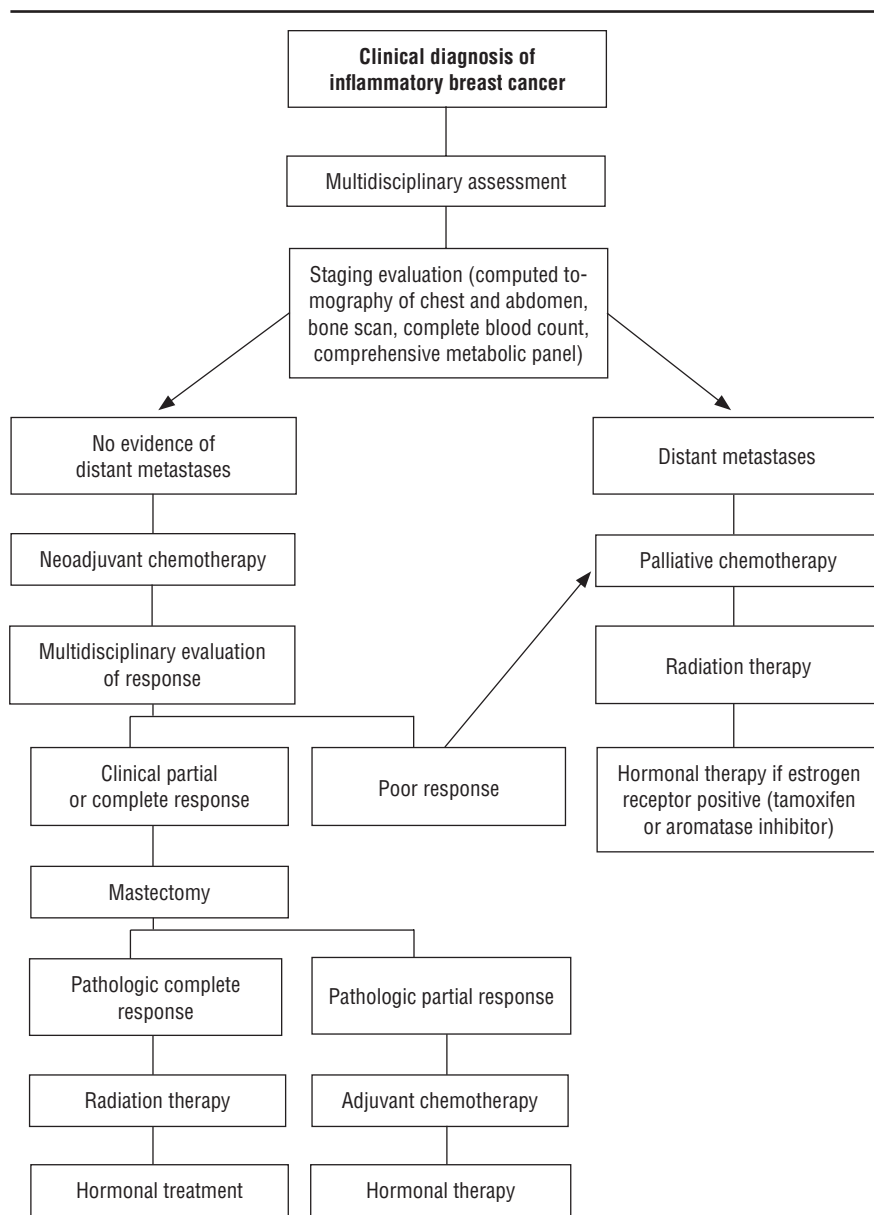


Figure 2. Treatment Algorithm for Inflammatory Breast Cancer

Clinical Highlights: Inflammatory Breast Cancer

Definition: Inflammatory breast cancer is a rapidly progressing, locally advanced (stage IIIa or IIIb) breast cancer characterized by a clinical triad of erythema, edema, and *peau d'orange* texture to the affected skin. The condition is rare, representing approximately 2% of breast cancers; however, the prognosis for inflammatory breast cancer is poor, with a three-year survival rate of 42% compared with 85% among patients with noninflammatory breast cancer.

Pathophysiology: The histopathology of inflammatory breast cancer is no different from that of other invasive breast cancers. It can present as ductal, lobular, medullary, or any of the other less common breast cancer phenotypes. What makes inflammatory breast cancer unique is the presence of breast cancer cells in the dermal lymphatics, which is determined by performing an incisional biopsy that includes skin tissue; however, not every case of inflammatory breast cancer is confirmed in this manner. Inflammatory breast cancer often is diagnosed purely on clinical presentation. Some distinguishing pathologic features appear to be associated strongly with inflammatory breast cancer: mutations in the *p53* gene and overexpression of HER2/neu, endothelial growth

factor receptors and cathepsin D, E-cadherin and *RhoC GTPase*. Most inflammatory breast cancer cases are hormone receptor negative and HER2/neu positive.

Risk factors: No known risk factors predispose patients to developing inflammatory breast cancer over noninflammatory breast cancer. Inflammatory breast cancer is seen in women of all ages and has the same characteristic presentation of a sudden onset of breast pain, erythema, and edema. Inflammatory breast cancer often is misdiagnosed in its early stages, especially in women who are lactating or recently have been pregnant, when it frequently is confused with mastitis.

Clinical findings: The classic triad of breast pain, redness, and breast swelling are the common presenting signs of inflammatory breast cancer. Patients often complain of a sudden onset of unilateral breast pain, closely followed by diffuse erythema in the painful breast. Edema becomes evident within a few days and gradually worsens. As edema increases, the nipple may flatten or invert. Mammograms reveal a discrete mass in less than 50% of patients who present with inflammatory breast cancer symptoms. An excisional biopsy may show adenocarcinoma in the dermal lymphatics, but lack of cancer cells in the

specimen should not preclude making the diagnosis of inflammatory breast cancer based on clinical findings.

Differential diagnosis: Mastitis, puerperal or nonpuerperal; cellulitis; and inflammatory breast cancer are possible diagnoses. If no infectious cause is found for the symptoms, inflammatory breast cancer should be considered the presumptive diagnosis until proven otherwise.

Treatment: Patients with newly diagnosed inflammatory breast cancer are treated with neoadjuvant chemotherapy, including an anthracycline and a taxane. Possible chemotherapy regimens include doxorubicin and cyclophosphamide (AC) followed by paclitaxel in patients who do not overexpress HER2/neu. Patients who are HER2/neu positive often are given weekly paclitaxel with trastuzumab first, followed by AC. Another option for HER2/neu-positive patients is docetaxel and carboplatin concurrent with trastuzumab. If a clinical response to chemotherapy occurs, mastectomy and radiation therapy should follow. Trastuzumab can be continued concurrently with radiation therapy and extend for a total of 12 months. Hormone manipulation is necessary if the cancer is hormone receptor positive.

twice-daily postmastectomy radiation to a total of 66 Gy resulted in improved locoregional control, disease-free survival, and overall survival and was well tolerated (Liao et al., 2000).

Historically, women who have had mastectomies for inflammatory breast cancer rarely have been offered breast reconstruction. A retrospective chart review of 23 women who underwent elective breast reconstruction after mastectomy for inflammatory breast cancer showed that 11 patients were alive 44 months after initial diagnosis (Chin et al., 2000). The researchers concluded that significant emotional and aesthetic benefits of reconstruction should be available to women with inflammatory breast cancer as part of the multimodal, comprehensive therapy currently being used to manage this aggressive disease (Chin et al.).

What is the outlook for women diagnosed with inflammatory breast cancer?

Inflammatory breast cancer constitutes approximately 2% of all malignant breast tumors (Chang, Parker, Pham, Buzdar, & Hursting, 1998) and has an incidence of 1%–6% in the United States. African Americans have a higher incidence than Caucasians and other ethnic groups (Cristofanilli et al., 2003). Since 1997, the incidence of

inflammatory breast cancer has increased at a rate greater than that of noninflammatory breast cancers (Chang et al., 1998). Despite the multimodality approach, the prognosis remains poor, with a three-year survival rate of 42% compared with 85% among patients with noninflammatory breast cancer (Chang et al., 1998). Inflammatory breast cancer is the most aggressive primary breast cancer, with clinical and biologic characteristics of a rapidly proliferating disease (Cristofanilli et al.). Increasing the awareness of the initial manifestations of inflammatory breast cancer among internists, gynecologists, and primary care providers can result in earlier diagnosis, thus increasing the odds of multidisciplinary evaluation and neoadjuvant chemotherapy before metastatic disease has occurred. Although the rarity of inflammatory breast cancer precludes large randomized clinical trials, continued research into angiogenic and molecular modulators may lead to significant progress in objective response, thereby improving overall prognosis.

Author Contact: Susan Moore, RN, MSN, ANP, AOCN®, can be reached at susan_h_moore@rush.edu, with copy to editor at rose_mary@earthlink.net.

References

- Azlina, A.F., Ariza, Z., Arni, T., & Hisham, A.N. (2003). Chronic granulomatous mastitis: Diagnostic and therapeutic considerations. *World Journal of Surgery*, 27, 515–518.
- Brewer, V.H., Hahn, K.A., Rohrbach, B.W., Bell, J.L., & Baddour, L.M. (2000). Risk factor analysis for breast cellulitis complicating breast conservation therapy. *Clinical Infectious Diseases*, 31, 654–659.
- Chang, H.R., Slamon, D., Chap, L., Apple, S., Glaspy, J., Lee, P., et al. (2005). Neoadjuvant taxotere (T), carboplatin (C), with or without herceptin (H) for T3 and T4 breast cancer [Abstract 845]. *Journal of Clinical Oncology*, 23(16, Suppl. 1), 89s.
- Chang, S., Parker, S.L., Pham, T., Buzdar, A.U., & Hursting, S.D. (1998). Inflammatory breast carcinoma incidence and survival: The Surveillance, Epidemiology, and End Results (SEER) program of the National Cancer Institute, 1975–1992. *Cancer*, 82, 2366–2372.
- Charafe-Jauffret, E., Tarpin, C., Bardou, V.J., Bertucci, F., Ginestier, C., Braud, A.C., et al. (2004). Immunophenotypic analysis of inflammatory breast cancers: Identification of an “inflammatory signature.” *Journal of Pathology*, 202, 265–273.
- Chin, P.L., Anderson, J.S., Somlo, G., Chu, D.Z., Schwarz, R.E., & Ellenhorn, J.D. (2000).

- Esthetic reconstruction after mastectomy for inflammatory breast cancer: Is it worthwhile? *Journal of the American College of Surgeons*, 190, 304–309.
- Cristofanilli, M., Buzdar, A.U., & Hortobagyi, G.N. (2003). Update on the management of inflammatory breast cancer. *Oncologist*, 8, 141–148.
- Galmarini, C.M., Garbovesky, C., Galmarini, D., & Galmarini, F.C. (2002). Clinical outcome and prognosis of patients with inflammatory breast cancer. *American Journal of Clinical Oncology*, 25, 172–177.
- Giordano, S.H., & Hortobagyi, G.N. (2003). Inflammatory breast cancer: Clinical progress and the main problems that must be addressed. *Breast Cancer Research*, 5, 284–288.
- Givens, M.L., & Luszczyk, M. (2002). Breast disorders: A review for emergency physicians. *Journal of Emergency Medicine*, 22, 59–65.
- Jaiyesimi, I.A., Buzdar, A.U., & Hortobagyi, G. (1992). Inflammatory breast cancer: A review. *Journal of Clinical Oncology*, 10, 1014–1024.
- Johnson, P. (2003). Inflammatory breast cancer in primary care. *Nurse Practitioner*, 28(5), 58–59.
- Kushwaha, A.C., Whitman, G.J., Stelling, C.B., Cristofanilli, M., & Buzdar, A.U. (2000). Primary inflammatory carcinoma of the breast: Retrospective review of mammographic findings. *American Journal of Roentgenology*, 174, 535–538.
- Lerebours, F., Bieche, I., & Lidereau, R. (2005). Update on inflammatory breast cancer. *Breast Cancer Research*, 7, 52–58.
- Liao, Z., Strom, E.A., Buzdar, A.U., Singletary, S.E., Hunt, K., Allen, P.K., et al. (2000). Locoregional irradiation for inflammatory breast cancer: Effectiveness of dose escalation in decreasing recurrence. *International Journal of Radiation Oncology, Biology, Physics*, 47, 1191–1200.
- Montemurro, F., & Aglietta, M. (2005). Incorporating trastuzumab into the neoadjuvant treatment of HER2-overexpressing breast cancer. *Clinical Breast Cancer*, 6, 77–80.
- Ozmen, V., Cabioglu, N., Igcı, A., Dagoglu, T., Aydinler, A., Kecer, M., et al. (2003). Inflammatory breast cancer: Results of anthracycline-based neoadjuvant chemotherapy. *Breast Journal*, 9, 79–85.
- Peters, F., Kiesslich, A., & Pahnke, V. (2002). Coincidence of nonpuerperal mastitis and non-inflammatory breast cancer. *European Journal of Obstetrics, Gynecology and Reproductive Biology*, 105, 59–63.
- Shenkier, T., Weir, L., Levine, M., Olivotto, I., Whelan, T., & Reyno, L. (2004). Clinical practice guidelines for the care and treatment of breast cancer: 15. Treatment for women with stage III or locally advanced breast cancer. *Canadian Medical Association Journal*, 170, 983–994.
- Staren, E.D., Klepac, S., Smith, A.P., Hartsell, W.F., Segretti, J., Witt, T.R., et al. (1996). The dilemma of delayed cellulitis after breast conservation therapy. *Archives of Surgery*, 131, 651–654.
- Tuma, R.S. (2005). Trastuzumab trials steal show at ASCO meeting. *Journal of the National Cancer Institute*, 97, 870–871.
- Turpin, E., Bieche, I., Bertheau, P., Plassa, L.F., Lerebours, F., de Roquancourt, A., et al. (2002). Increased incidence of ERBB2 overexpression and TP53 mutation in inflammatory breast cancer. *Oncogene*, 21, 7593–7597.
- van Golen, K.L. (2003). Inflammatory breast cancer: Relationship between growth factor signaling and motility in aggressive cancers. *Breast Cancer Research*, 5, 174–179.
- van Golen, K.L., Wu, Z.F., Qiao, X.T., Bao, L.W., & Merajver, S.D. (2000). RhoC GTPase, a novel transforming oncogene for human mammary epithelial cells that partially recapitulates the inflammatory breast cancer phenotype. *Cancer Research*, 60, 5832–5838.
- Zippel, D., Siegelmann-Danieli, N., Ayalon, S., Kaufman, B., Pfeffer, R., & Zvi Papa, M. (2003). Delayed breast cellulitis following breast conserving operation. *European Journal of Surgical Oncology*, 29, 327–330. 